



PATIENT PRESENTING CLINICAL SIGNS

Chaos Ciolfi difficulty walking, whimpering in pain, shaking, lethargic, not eating, panting When? 3/4 days she has been declining- was okay and then started to become less mobile (O thought she just pulled a muscle) Had a birthday party last Sunday and she may have eaten something but not sure as she was still active and ok (other than acting a bit sore) on Tuesday (when vaccines were done), Lives on a farm and Chaos often runs around there .

SPECIES

Canine Abnormal PE/Chem/CBC/UA Results: SEVER PAIN RESPONSE WHEN PALPATING RIGHT FEMUR AND LUMBO-SACRAL AREA cPL is high

BREED

RADIOGRAPHIC STUDY OF THE ABOMEN & PELVIS

Rottweiler

Radiographs of the abdomen in three imaging planes and a VD view of the pelvis are provided for review.

SEX

RADIOGRAPHIC FINDINGS

Female Spayed

The vertebral endplates of het lumbosacral junction present mild to moderate spondylosis formation. The remainder of the lumbar spine are within normal limits.

AGE

At the transition between the right femoral head & neck, very mild osteophyte formation is appreciated. Proximal to the greater trochanter of the femur bilaterally, multiple roundish mineralized bodies measuring up to 7 mm in size are appreciated.

7 Years

No abnormalities of the extraabdominal soft tissues are noted. The abdominal wall is smooth and thin.

INTERPRETED BY

The serosal detail is maintained throughout the peritoneal and retroperitoneal space.

Sebastian Schaub, DVM
Dr. med. vet. DipECVDI

The liver is appropriate in position, size and presents uniform opacity.

HOSPITAL NAME

The splenic head is in the anticipated position and within normal limits for size and opacity. The splenic body and tail are considered normal for position, size, shape and opacity.

St. Catherine's Animal Hospital

Both kidneys are seen and present with normal size, shape, delineation and opacity. The urinary bladder is in its anticipated position. No radiopaque calculi are noted throughout the upper and lower urinary tract.

REFERRING VET

The stomach is in its anticipated position and is mildly distended by gas.

Dr. Boctor

The small intestinal loops are of even diameter and non-dilated, a small amount of gas is seen within the small intestinal loops and considered within normal limits.

The colon is seen in the expected position and presents with appropriate content.

INVOICE

RADIOGRAPHIC DIAGNOSIS

54119

- Very mild degenerative osteoarthritis right coxofemoral joint
- Spondylosis deformans lumbosacral junction
- Metaplasia tendon gluteus medius muscle bilaterally
- Mild aerophagia . might be due to stress or pain

DATE

9-19-22



PATIENT

Chaos Ciolfi

SPECIES

Canine

BREED

Rottweiler

SEX

Female Spayed

AGE

7 Years

INTERPRETED BY

Sebastian Schaub, DVM
Dr. med. vet. DipECVDI

HOSPITAL NAME

St. Catherine's Animal
Hospital

REFERRING VET

Dr. Boctor

INVOICE

54119

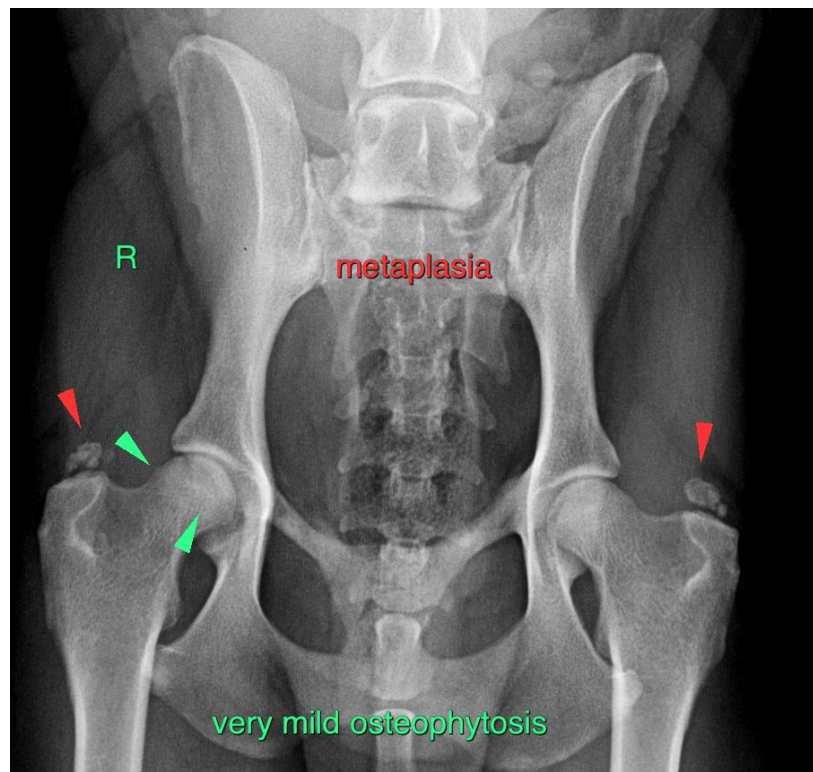
DATE

9-19-22

INTERPRETATION OF THE FINDINGS & FURTHER RECOMMENDATIONS

An underlying cause for the pain in the sacral region/along the right femur is not appreciated. Given the acute onset of clinical signs rule out traumatic insult, intervertebral disc disease, inflammation.

The abdomen presents without pathologies.



The information and recommendations provided are based on the images presented by the referring veterinarian/sonographer. No evaluation can be communicated regarding pathology that was not visible in the image/video clips provided.

Thank you for this referral. If the clinical or image interpretation does not parallel your findings or if I can be of any further assistance please contact me.

Sebastian Schaub, Sebastian Schaub, DVM, Dr. med. vet. DipECVDI
sebast.schaub@gmail.com