



PATIENT

Buffy Jackson

PRESENTING CLINICAL SIGNS

PREVIOUS CRYPTORCHID- 2ND TESTICAL WAS NEVER FOUND IN ABDOMEN OR INGUINAL DURING SX AT 7 MONTHS OLD. LOOKING FOR 2ND TESTICAL OR REASON FOR INAPPROPRIATE URINATION. TWO CATS AT HOME; TWO LITTER BOXES BUFFY WILL SPONTANEOUSLY URINATE- ON THE STAIRS, UNDER THE TABLE, JUST WHERE EVER. NORMAL UA 9/13/22

SPECIES

Feline

Abnormal PE/Chem/CBC/UA Results:

COMPUTED TOMOGRAPHY OF THE ABDOMEN

BREED

DSH

A high resolution pre- and post-contrast CT study of the abdomen is provided for review.

COMPUTED TOMOGRAPHIC FINDINGS

SEX

MN

The serosal fat presents normal attenuation behavior. There is no evidence of peritoneal effusion or peritonitis.

Both kidneys present within normal limits for size, shape and organ architecture. After contrast administration a bilaterally symmetric and uniform nephro- and pyelogram is noted.

The adrenal glands are within normal limits for size, shape and organ architecture.

AGE

1.5 Years

Both liver and spleen present with normal shape, even surface, uniformly attenuating parenchyma and homogeneous contrast enhancement, unremarkable.

The portal vein presents a normal order of its tributary veins and intrahepatic branching. No abnormal vessel is noted inside and outside of the liver parenchyma.

INTERPRETED BY

Sebastian Schaub, DVM
Dr. med. vet. DipECVDI

The pancreas is evenly contoured, the pancreatic parenchyma is homogeneous and presents uniform contrast enhancement.

HOSPITAL NAME

Scottsdale Veterinary
Clinic

The position, delineation, wall and content of the gastrointestinal tract are considered within normal limits throughout.

The right testicle is located in the subcutaneous tissue ventral to the pelvic floor, approximately level with the obturator foramen.

COMPUTED TOMOGRAPHIC DIAGNOSIS

REFERRING VET

Dr. Horsley

- Right sided inguinal cryptorchism

INTERPRETATION OF THE FINDINGS & FURTHER RECOMMENDATIONS

The right testicle is located in the subcutaneous tissue ventral to the pelvis, level with the obturator foramen.

INVOICE

54139

DATE

9-19-22



PATIENT

Buffy Jackson

SPECIES

Feline

BREED

DSH

SEX

MN

AGE

1.5 Years

INTERPRETED BY

Sebastian Schaub, DVM
Dr. med. vet. DipECVDI

HOSPITAL NAME

Scottsdale Veterinary
Clinic

REFERRING VET

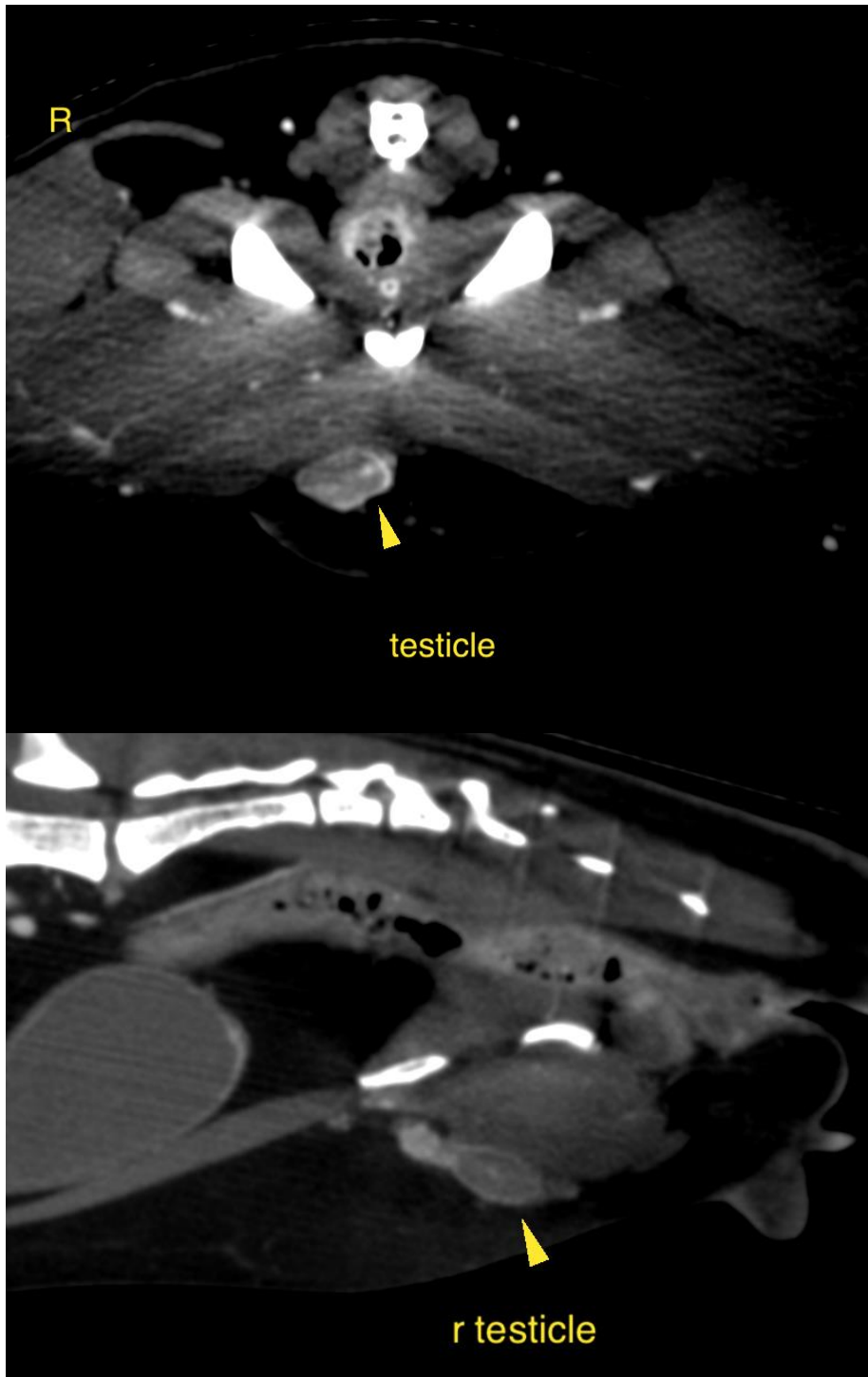
Dr. Horsley

INVOICE

54139

DATE

9-19-22





PATIENT

Buffy Jackson

The information and recommendations provided are based on the images presented by the referring veterinarian/sonographer. No evaluation can be communicated regarding pathology that was not visible in the image/video clips provided.

SPECIES

Feline

Thank you for this referral. If the clinical or image interpretation does not parallel your findings or if I can be of any further assistance please contact me.

BREED

DSH

Sebastian Schaub, Sebastian Schaub, DVM, Dr. med. vet. DipECVDI
sebast.schaub@gmail.com

SEX

MN

AGE

1.5 Years

INTERPRETED BY

Sebastian Schaub, DVM
Dr. med. vet. DipECVDI

HOSPITAL NAME

Scottsdale Veterinary
Clinic

REFERRING VET

Dr. Horsley

INVOICE

54139

DATE

9-19-22