



PATIENT PRESENTING CLINICAL SIGNS

Dash Busto History: Multiple nails irregular shape and color, some have cracks near the base, others very friable/crumbly, several are just a short nub of an irregular nail. The 2nd digit left front is broken off near the base and the adjacent fur is matted with dried blood...very painful to touch

SPECIES Abnormal PE/Chem/CBC/UA Results:

Canine RADIOGRAPHIC STUDY OF THE FRONT PAWS

Radiographs of the front paws in a dorsopalmar and mediolateral view are provided for review.

BREED RADIOGRAPHIC FINDINGS

Wheaten Terrier The nail of the second left digit and fourth right digit is moderately shortened. Abaxial deviation of the tip of the nail of the third right digit is seen with lateral kinking of the most distal aspect of the distal phalanx.

SEX The nails of the remaining digits appear elongated.

Spayed Female

RADIOGRAPHIC DIAGNOSIS

- Shortened nails second digit left front paw and fourth digit right front paw
- Suspect fractured distal tip of the distal phalanx third digit right front limb

14 Years

INTERPRETATION OF THE FINDINGS & FURTHER RECOMMENDATIONS

INTERPRETED BY

Sebastian Schaub, DVM Dr. med. vet. DipECVDI

History of changes of the nails without signs of osteolysis or overt inflammation of the respective digits. Rule out traumatic insult versus immune mediated disease versus infection – a demeratology consult might be beneficial in this case.

HOSPITAL NAME

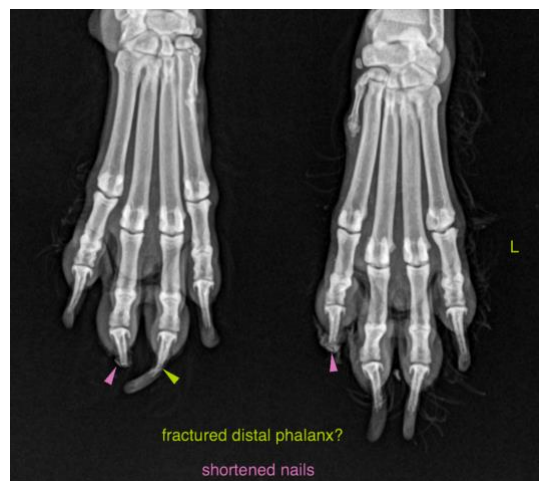
DPC Veterinary H

REFERRING VET

Dr. Feldt

INVOICE

13159



DATE

9/18/21

The information and recommendations provided are based on the images presented by the referring veterinarian. No evaluation can be communicated regarding pathology that was not visible in the image/video clips provided.



PATIENT

Dash Busto

Thank you for this referral. If the clinical or image interpretation does not parallel your findings or if I can be of any further assistance please contact me.

SPECIES

Canine

Sebastian Schaub, Sebastian Schaub, DVM, Dr. med. vet. DipECVDI
sebast.schaub@gmail.com

BREED

Wheaten Terrier

SEX

Spayed Female

AGE

14 Years

INTERPRETED BY

Sebastian Schaub,
DVM Dr. med. vet.
DipECVDI

HOSPITAL NAME

DPC Veterinary H

REFERRING VET

Dr. Feldt

INVOICE

13159

DATE

9/18/21