



**PATIENT**

Bullet Gibson

**PRESENTING CLINICAL SIGNS**

Patient had a mass in the left ear canal (removed and biopsied post CT).

**SPECIES**

Feline

**COMPUTED TOMOGRAPHY OF THE SKULL AND THORAX**

A high resolution pre- and post-contrast CT study of the skull and thorax are provided for review.

**BREED**

DSH

Skull

Multiple incisor teeth are absent. A significant amount of mineral attenuating material is attached to the crowns of the premolar and molar teeth in the upper and lower jaw quadrants. The alveolar bone in all jaw quadrants presents a coarse trabecular pattern and heterogeneous sclerosis. The periodontal space of triadan 104&404 is moderately irregular widened.

**SEX**

MN

The nasal cavity presents the expected aerated spaces between thin & even conchae and turbinates with smooth mucosal lining.

**AGE**

13 Years

Both temporomandibular joints present congruent joint spaces with even subchondral bone surfaces and are considered within normal limits.

**INTERPRETED BY**

Sebastian Schaub, DVM  
Dr. med. vet. DipECVDI

The left tympanic bulla is filled with non-contrast enhancing soft tissue material. The osseous lining of the left tympanic bulla is moderately to markedly irregular thickened. Lysis of the tympanic part of the left temporal bone with perforation of the cranial fossa is present. The wall of the left external ear canal is moderately thickened with heterogeneous contrast enhancement. The left external ear canal contains post contrast mild amount of hypoattenuating material.

**HOSPITAL NAME**

Animal Surgical  
Center

The brain presents no deviation from normal anatomy and symmetry. The brain parenchyma is homogeneous and within normal limits for attenuation and distribution of contrast enhancement. The ventricular system is non-dilated and symmetric.

The left mandibular lymph nodes and the left medial retropharyngeal lymph node are prominent, uniform soft tissue attenuating and contrast enhancing.

**REFERRING VET**

Dr. T Infernuso

Extensive synostosis between the right radius & ulna is seen.

Thorax

The vertebral end plates T7/T8 present moderate spondylosis formation.

**INVOICE**

47443

The sternal, cranial mediastinal and tracheobronchial lymph nodes are small elongated with a normal short-to-long-axis-ratio is < 0.5, the attenuation and contrast enhancement pattern is uniform and considered within normal limits.

**DATE**

9-17-21

The cardiovascular structures including the pulmonary vasculature are within normal limits.

The bronchial tree presents with regular branching and tapers uniformly towards the periphery as expected, the bronchial walls are thin and smooth. The bronchus-to-artery ratio is within normal limits.

**PATIENT**

Bullet Gibson

The right cranial lung lobe presents multiple ill-defined consolidated regions in the subpleural space. The remainder of the lung parenchyma present the expected architecture and attenuation behavior.

**SPECIES**

Feline

Small incidental gas pockets are seen within the esophageal lumen, there is no evidence of abnormal dilation.

**COMPUTED TOMOGRAPHIC DIAGNOSIS****BREED**

DSH

- Left sided chronic otitis externa
- Left sided chronic otitis media with perforation of the cranial fossa – no signs for meningitis/encephalitis
- Generalized chronic periodontal disease – most accentuated 104&404 with chronic osteitis of the alveolar bone in all jaw quadrants
- Lymphadenopathy left mandibular and medial retropharyngeal lymph node
- Moderate to marked dental tartar
- Multiple small consolidated subpleural regions right cranial lung lobe
- Spondylosis deformans
- Synostosis right antebrachium – possible history of trauma

**AGE**

13 Years

**INTERPRETATION OF THE FINDINGS & FURTHER RECOMMENDATIONS****INTERPRETED BY**

Sebastian Schaub, DVM  
Dr. med. vet. DipECVDI

The findings of the current CT study are consistent with chronic left sided otitis externa and media. No distinct mass can be appreciated in the left external ear canal, but this is likely due to marked thickening of the wall merging with the intraluminal mass. Biopsy of the mass has already been performed for further definition. A left sided total ear canal ablation including lateral bulla osteotomy appears beneficial in this case – be aware for careful curettage of the medial aspect due to perforation of the cranial fossa.

**HOSPITAL NAME**

Animal Surgical  
Center

Recommend FNA sampling of the prominent tributary lymph nodes to rule out malignant transformation.

A complete dental workup with extraction of at least 104&404 should be considered.

**REFERRING VET**

Dr. T Infernuso

The consolidated subpleural lesion of the right cranial lung lobe are most consistent with dystelectasis or small regions of pneumonitis/granuloma formation.

**INVOICE**

47443

**DATE**

9-17-21



**PATIENT**

Bullet Gibson

**SPECIES**

Feline

**BREED**

DSH

**SEX**

MN

**AGE**

13 Years

**INTERPRETED BY**

Sebastian Schaub, DVM  
Dr. med. vet. DipECVDI

**HOSPITAL NAME**

Animal Surgical  
Center

**REFERRING VET**

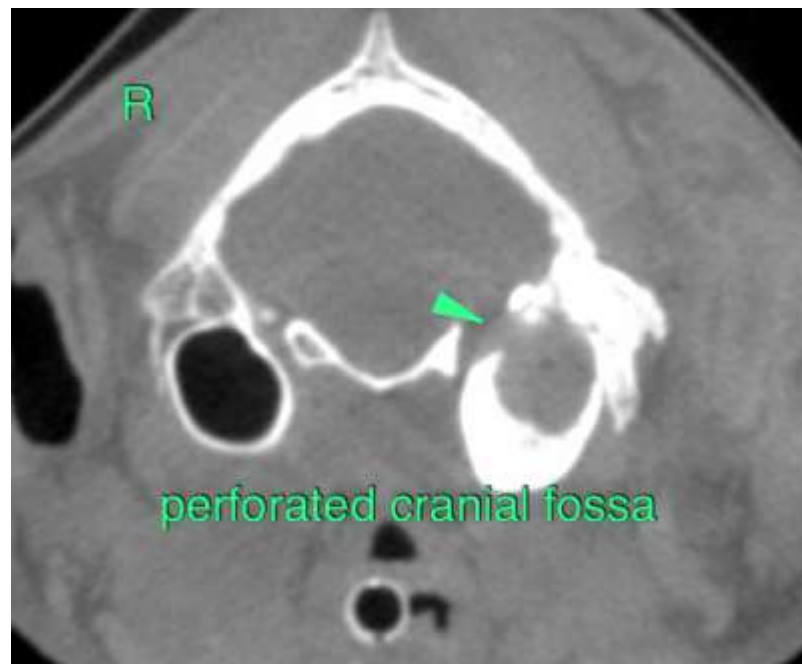
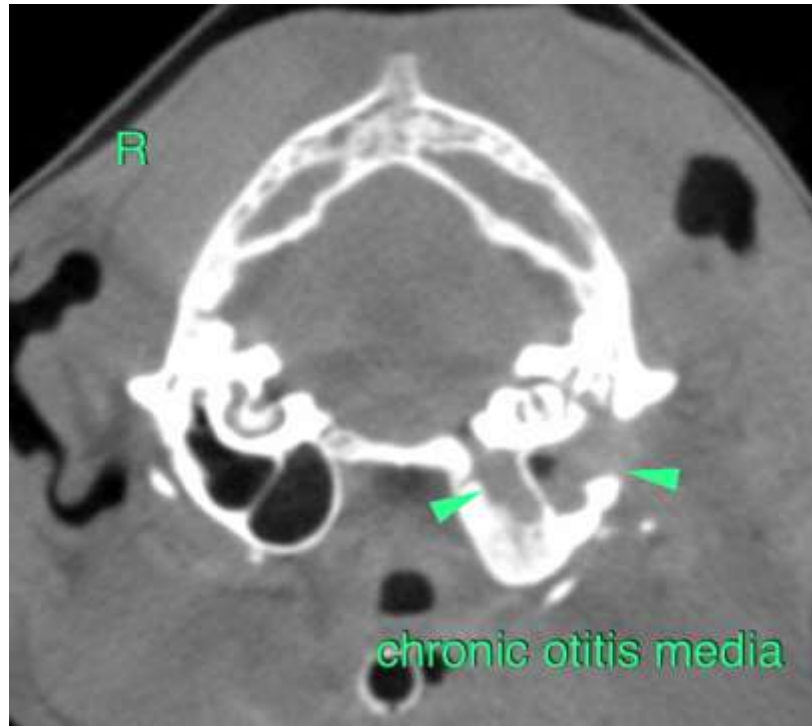
Dr. T Infernuso

**INVOICE**

47443

**DATE**

9-17-21





**PATIENT**

Bullet Gibson

**SPECIES**

Feline

**BREED**

DSH

**SEX**

MN

**AGE**

13 Years

**INTERPRETED BY**

Sebastian Schaub, DVM  
Dr. med. vet. DipECVDI

**HOSPITAL NAME**

Animal Surgical  
Center

**REFERRING VET**

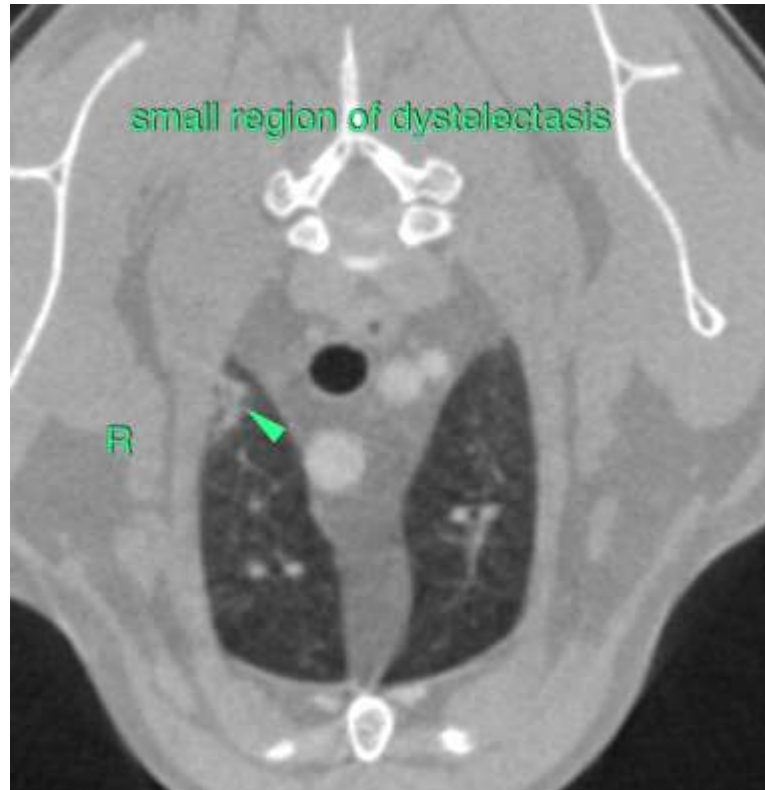
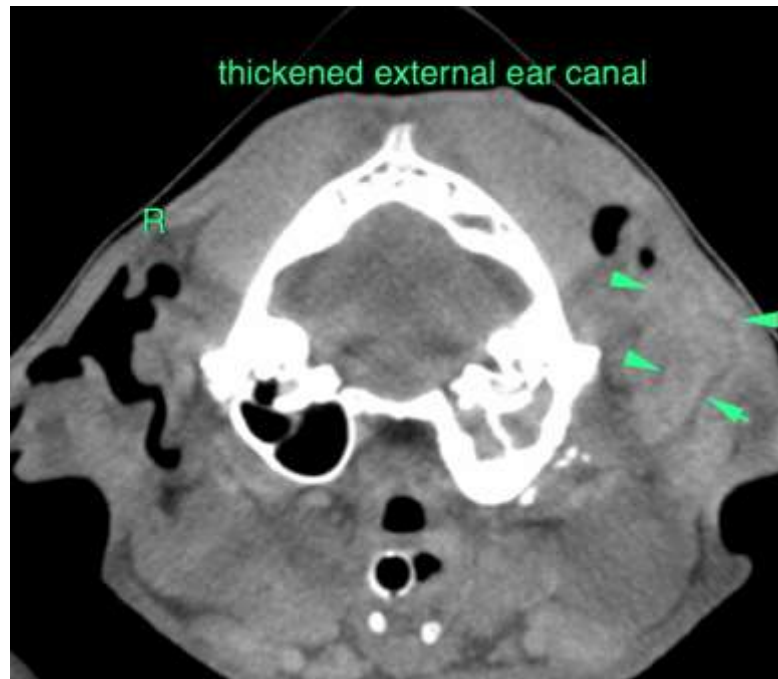
Dr. T Infernuso

**INVOICE**

47443

**DATE**

9-17-21





**PATIENT**

Bullet Gibson

**SPECIES**

Feline

**BREED**

DSH

**SEX**

MN

**AGE**

13 Years

**INTERPRETED BY**

Sebastian Schaub, DVM  
Dr. med. vet. DipECVDI

**HOSPITAL NAME**

Animal Surgical  
Center

**REFERRING VET**

Dr. T Infernuso

**INVOICE**

47443

**DATE**

9-17-21

The information and recommendations provided are based on the images presented by the referring veterinarian. No evaluation can be communicated regarding pathology that was not visible in the image/video clips provided.

Thank you for this referral. If the clinical or image interpretation does not parallel your findings or if I can be of any further assistance please contact me.

**Sebastian Schaub**, Sebastian Schaub, DVM, Dr. med. vet. DipECVDI  
sebast.schaub@gmail.com