
PATIENT PRESENTING CLINICAL SIGNS

Mia Villagio Draining tracts below both eyes. Rule out dental abscessation vs other.

COMPUTED TOMOGRAPHIC STUDY OF THE SKULL
SPECIES

Canine

A high resolution pre- and post-contrast CT study of the skull ais provided for review.

COMPUTED TOMOGRAPHIC FINDINGS
BREED

Morkie

The tooth elements 209, 210, 311, 401 and 411 are absent. Triadan 108&208 present a significant periapical widening of the periodontal space. Mild to moderate subcutaneous swelling is seen level with the roots of triadan 108&208. Moderate horizontal bone loss is appreciated level with the maxillary & mandibular incisor teeth. A small, retained fragment of the buccal root of triadan 210 is appreciated within the alveolar bone – no signs of widening of the periodontal space.

SEX

Spayed Female

The lens of the right ocular bulb presents mild peripheral mineralization.

The nasal cavity presents the expected aerated spaces between thin & even conchae and turbinates with smooth mucosal lining.

AGE

13 Years

Both temporomandibular joints present congruent joint spaces with even subchondral bone surfaces and are considered within normal limits.

INTERPRETED BY

Sebastian Schaub,
DVM Dr. med. vet.
DipECVDI

Both tympanic bullae are aerated, the mucosal lining is not seen, the bony wall is smooth and thin. The external ear canals present a significant thickening of the wall and the lumen is obliterated. The epithelial lining of the opening of the external ear canal bilaterally is moderately thickened and contrast enhancing.

The brain presents no deviation from normal anatomy and symmetry. The brain parenchyma is homogeneous and within normal limits for attenuation and distribution of contrast enhancement. The ventricular system is non-dilated and symmetric.

HOSPITAL NAME

Mobile Pet Imaging

The mandibular lymph nodes are prominent.

COMPUTED TOMOGRAPHIC DIAGNOSIS
REFERRING VET

Dr. Meaux

- Bilateral otitis externa with marked hypertrophy of the epithelial lining
- Bilateral periodontal abscess/granuloma formation 108&208
- Periodontal disease maxillary & mandibular incisor teeth
- Lymphadenopathy mandibular lymph nodes
- Absent triadan 209, 210, 311, 401 and 411
- Suspect cataract formation/sclerosis of the lens right eye

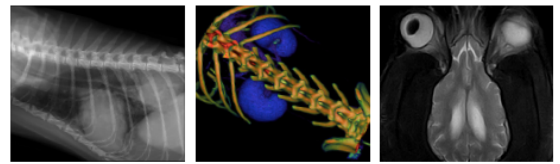
INVOICE

41369

INTERPRETATION OF THE FINDINGS & FURTHER RECOMMENDATIONS
DATE

9/15/22

The CT findings are compatible with periodontal abscess formation of triadan 108&208 with accompanying soft tissue swelling – a plausible explanation for the presenting clinical signs and extraction of the affected teeth has already been performed regarding the history.



PATIENT Mia Villagio
 There is evidence of bilateral otitis externa with stenosis of the external ear canals due to significant hypertrophy of the epithelial lining without signs of accompanying otitis media. Secondary reactive hyperplasia of the mandibular lymph nodes.

SPECIES

Canine

BREED

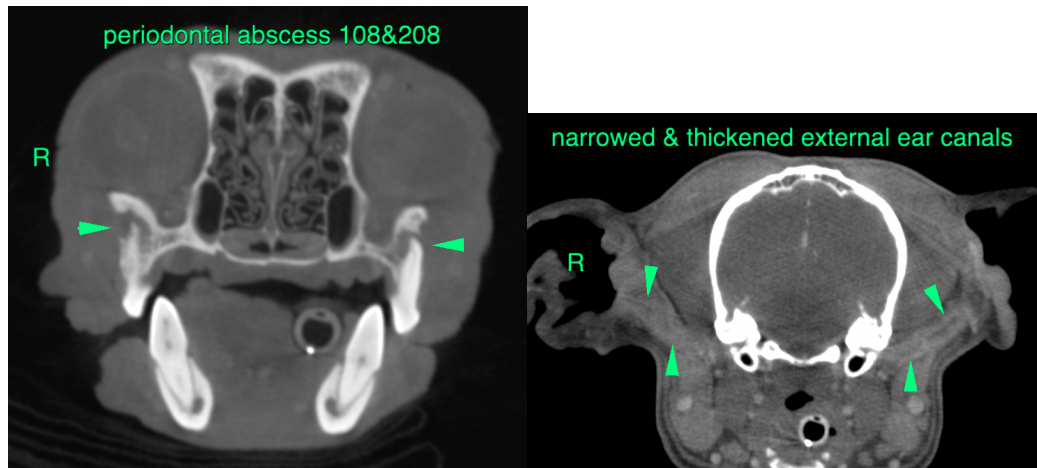Morkie

SEX

Spayed Female

AGE

13 Years



The information and recommendations provided are based on the images presented by the referring veterinarian. No evaluation can be communicated regarding pathology that was not visible in the image/video clips provided.

INTERPRETED BY

Sebastian Schaub,
 DVM Dr. med. vet.
 DipECVDI

Thank you for this referral. If the clinical or image interpretation does not parallel your findings or if I can be of any further assistance please contact me.

Sebastian Schaub, Sebastian Schaub, DVM, Dr. med. vet. DipECVDI
 sebast.schaub@gmail.com

HOSPITAL NAME

Mobile Pet Imaging

REFERRING VET

Dr. Meaux

INVOICE

41369

DATE

9/15/22