



PATIENT

Dexter Helwig

PRESENTING CLINICAL SIGNS

LIMPING ON RIGHT HIND. BLOODWORK UNREMARKABLE.
Abnormal PE/Chem/CBC/UA Results:

SPECIES

Canine

RADIOGRAPHIC STUDY OF THE STIFLE JOINTS

Radiographs of the right stifle joint in two orthogonal imaging planes are provided for review.

BREED

Boxer Mix

RADIOGRAPHIC FINDINGS

The right stifle joint presents smooth osseous margins and without evidence of intracapsular swelling. The patella is in situ in the craniocaudal projection.

The soft tissue shadow of the right popliteal lymph node is mildly prominent.

RADIOGRAPHIC DIAGNOSIS

SEX

Male

- Lymphadenopathy right popliteal lymph node
- Normal right stifle joint

AGE

12 Years

INTERPRETATION OF THE FINDINGS & FURTHER RECOMMENDATIONS

The radiographic study of the right stifle joint presents without abnormalities, explaining the history of lameness. The prominent right popliteal lymph node might present a normal anatomical variant, however FNA sampling can be used to rule out inflammatory or neoplastic infiltrative disease.

Rule out lameness originating from the proximal or distal aspects of the right hind limb or lameness of the left hind limb as there is evidence of degenerative joint disease of the left coxofemoral joint.

INTERPRETED BY

Sebastian Schaub, DVM
Dr. med. vet. DipECVDI

HOSPITAL NAME

St. Catherine's Animal
Hospital

REFERRING VET

Dr. Boctor

INVOICE

54086

DATE

9-15-22



PATIENT

Dexter Helwig

SPECIES

Canine

BREED

Boxer Mix

SEX

Male

AGE

12 Years

INTERPRETED BY

Sebastian Schaub, DVM
Dr. med. vet. DipECVDI

HOSPITAL NAME

St. Catherine's Animal
Hospital

REFERRING VET

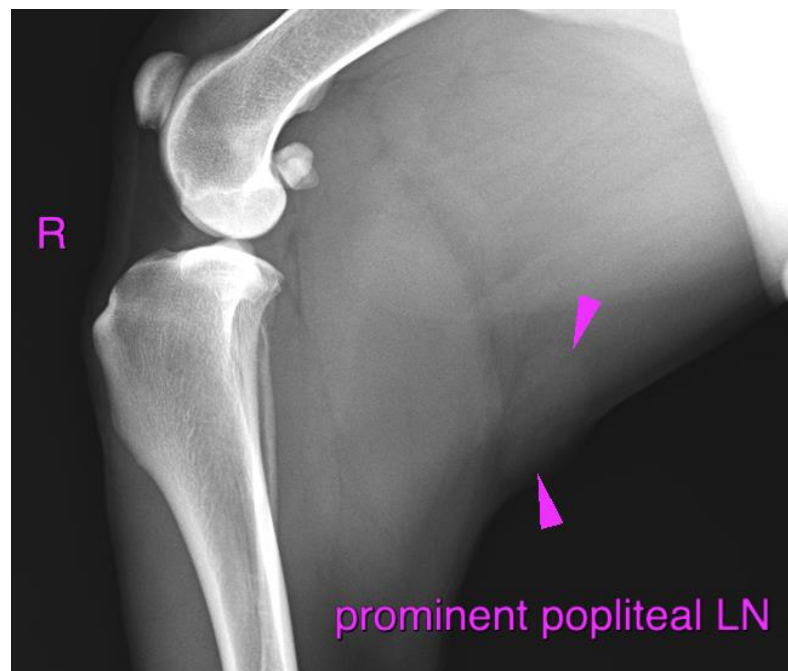
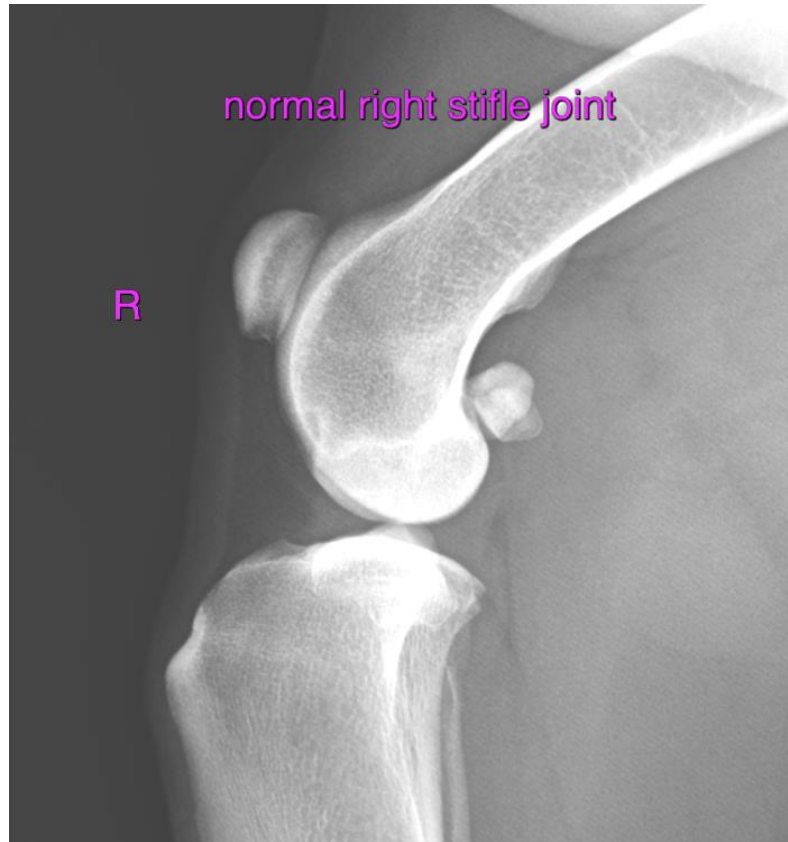Dr. Boctor

INVOICE

54086

DATE

9-15-22





PATIENT

Dexter Helwig

SPECIES

Canine

The information and recommendations provided are based on the images presented by the referring veterinarian/sonographer. No evaluation can be communicated regarding pathology that was not visible in the image/video clips provided.

BREED

Boxer Mix

Thank you for this referral. If the clinical or image interpretation does not parallel your findings or if I can be of any further assistance please contact me.

Sebastian Schaub, Sebastian Schaub, DVM, Dr. med. vet. DipECVDI
sebast.schaub@gmail.com

SEX

Male

AGE

12 Years

INTERPRETED BY

Sebastian Schaub, DVM
Dr. med. vet. DipECVDI

HOSPITAL NAME

St. Catherine's Animal
Hospital

REFERRING VET

Dr. Boctor

INVOICE

54086

DATE

9-15-22