



**PATIENT PRESENTING CLINICAL SIGNS**

**Coco Kang** History: Coco, a 8 year old, FS Chihuahua X, presented to the AHP Neurology Service on September 7, 2021 for evaluation of seizures. Around 7:30 PM on August 19th, Mrs Kang took Coco for a 30 minute walk. At home, Coco developed difficulty walking, fell over and her limbs became rigid and were shaking (was unresponsive). It lasted 1 minute. She then recovered, started circling and was fly-biting. She had a second episode. No autonomous signs.

**SPECIES** Canine Abnormal PE/Chem/CBC/UA Results:

**MAGNETIC RESONANCE IMAGING OF THE SKULL**

**BREED** Chihuahua X T2 weighted, FLAIR, diffusion weighted, T1 pre- and post-gadolinium sequence in multiple plane areas provided for review.

**MAGNETIC RESONANCE IMAGING FINDINGS**

**SEX** Spayed Female The brain presents the expected anatomy and bilateral symmetry with normal signal intensity and contrast enhancement. There is no evidence of abnormal meningeal enhancement.

The ventricular system presents the expected dimensions, morphology and the CSF signal is within normal limits in all sequences.

**AGE**

8 Years The tympanic bullae are aerated and the bony lining is thin.

A small wart-like cutaneous lesion is seen dorsally to the right frontal sinus.

**INTERPRETED BY MAGNETIC RESONANCE IMAGING DIAGNOSIS**

Sebastian Schaub, DVM Dr. med. vet. DipECVDI

- Structural normal brain
- Wart like cutaneous lesion dorsal to frontal sinuses

**HOSPITAL NAME INTERPRETATION OF THE FINDINGS & FURTHER RECOMMENDATIONS**

Animal Health Partners In the present study of the brain there is no evidence of macromorphological disease, explaining the described clinical signs.

**REFERRING VET** If not yet done so the workup should be complemented by examination of CSF and complete bloodwork to screen for brain disease that is not necessarily associated with structural changes of the brain parenchyma and rule out hepatoencephalopathy and other systemic illness.

Dr. Little

**INVOICE**

13145

**DATE**

9/15/21



**PATIENT**

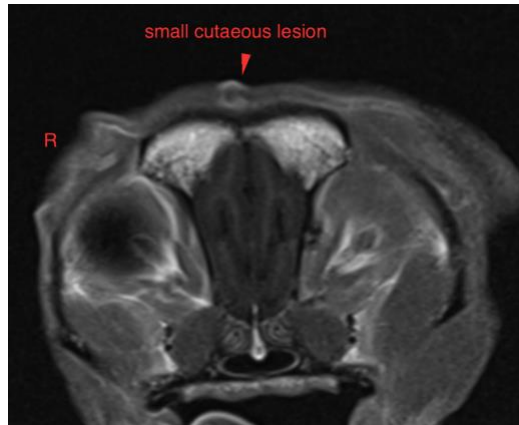
Coco Kang

**SPECIES**

Canine

**BREED**

Chihuahua X



**SEX**

Spayed Female

**AGE**

8 Years

The information and recommendations provided are based on the images presented by the referring veterinarian. No evaluation can be communicated regarding pathology that was not visible in the image/video clips provided.

Thank you for this referral. If the clinical or image interpretation does not parallel your findings or if I can be of any further assistance please contact me.

**Sebastian Schaub**, Sebastian Schaub, DVM, Dr. med. vet. DipECVDI  
sebast.schaub@gmail.com

**INTERPRETED BY**

Sebastian Schaub,  
DVM Dr. med. vet.  
DipECVDI

**HOSPITAL NAME**

Animal Health  
Partners

**REFERRING VET**

Dr. Little

**INVOICE**

13145

**DATE**

9/15/21