



**PATIENT PRESENTING CLINICAL SIGNS**

Shadow Sloan History: Intermittent cough  
Abnormal PE/Chem/CBC/UA Results: PE: NSF CBC/chem: NSF

**SPECIES RADIOGRAPHIC STUDY OF THE THORAX**

Canine A complete set of radiographs of the thorax is provided for review.

**RADIOGRAPHIC FINDINGS**

**BREED**  
Poodle The surrounding bony structures are within normal limits.  
The extrathoracic soft tissues present homogeneous without abnormalities.

**SEX**  
Neutered Male The heart is of normal size and shape, there is no evidence of cardiac chamber or vascular enlargement. The pulmonary vasculature is within normal limits.

**AGE**  
11 Years The cranial mediastinum presents the expected soft tissue opacity. The mediastinal width is less than twice the width of the vertebral column at the same level.

The trachea is normal in diameter and presents the anticipated course. The luminal outline of the trachea is smooth.

**INTERPRETED BY** The bronchial tree presents with thin walls and tapers uniformly towards the periphery as expected.

Sebastian Schaub, DVM Dr. med. vet. DipECVDI The lung parenchyma presents the expected architecture and opacity; the intrapulmonary vascular branching is seen up to the third order lung vessels.

**HOSPITAL NAME** The diaphragm is well delineated with even surface and the expected mild cranial bulging of the diaphragmatic cupola.

Sunset AH **RADIOGRAPHIC DIAGNOSIS**

- Normal thorax
- Moderate amount of pericardial fat

Christina Polit **INTERPRETATION OF THE FINDINGS & FURTHER RECOMMENDATIONS**

**INVOICE**  
13077 The radiographic study of the thorax presents no abnormalities, but normal age related mild changes of the pulmonary parenchyma. However, negative radiographs do not rule out potential bronchitis which appears a plausible explanation for the described clinical signs. Bronchoscopy including BAL might be used as advanced diagnostic tests.

**DATE**

9/14/21



**PATIENT**

Shadow Sloan

**SPECIES**

Canine

**BREED**

Poodle

**SEX**

Neutered Male

**AGE**

11 Years

**INTERPRETED BY**

Sebastian Schaub,  
DVM Dr. med. vet.  
DipECVDI

**HOSPITAL NAME**

Sunset AH

**REFERRING VET**

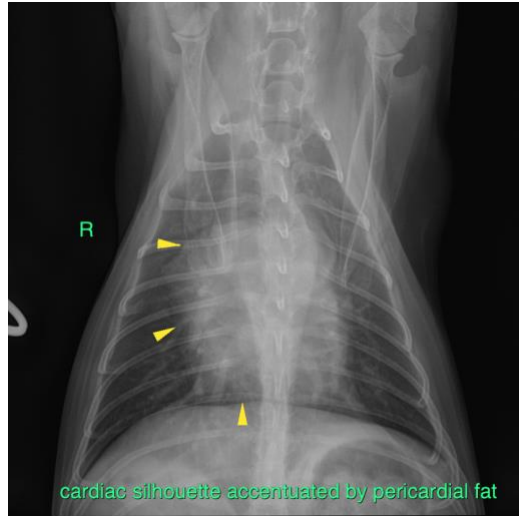
Christina Polit

**INVOICE**

13077

**DATE**

9/14/21



**The information and recommendations provided are based on the images presented by the referring veterinarian. No evaluation can be communicated regarding pathology that was not visible in the image/video clips provided.**

Thank you for this referral. If the clinical or image interpretation does not parallel your findings or if I can be of any further assistance please contact me.

**Sebastian Schaub**, Sebastian Schaub, DVM, Dr. med. vet. DipECVDI  
sebast.schaub@gmail.com