

**PATIENT PRESENTING CLINICAL SIGNS**

Rain Schreiber History: Patient presented on 09/14/21 with concerns of intermittent diarrhea, vomiting and lethargy since last Friday.

SPECIES Abnormal PE/Chem/CBC/UA Results:

Canine **RADIOGRAPHIC STUDY OF THE ABDOMEN**

A complete set of radiographs of the abdomen is provided for review.

BREED **RADIOGRAPHIC FINDINGS**

German Shepherd Mix
The surrounding bony structures are within normal limits.

SEX

Female
No abnormalities of the extraabdominal soft tissues are noted. The abdominal wall is smooth and thin. The serosal detail is moderately decreased, especially level with the intestinal tract. In the VD projection along the left abdominal wall, multiple small gas bubbles that cannot be located within an intestinal loop are seen and a gas opaque rim is accentuating the diaphragm. In the lateral projection gas can be seen between the stomach and the liver as well as the dorsal aspect of the fundus.

AGE

An ill-defined roundish soft tissue opaque structure is seen in the caudal abdomen, cranial to the urinary bladder.

2 Years 1 Month **RADIOGRAPHIC DIAGNOSIS**

INTERPRETED BY

- Septic peritonitis with moderate pneumoperitoneum
- Soft tissue opaque structure in caudal abdomen, associated with intestinal loops

Sebastian Schaub,
DVM Dr. med. vet.
DipECVDI

INTERPRETATION OF THE FINDINGS & FURTHER RECOMMENDATIONS

There is evidence of moderate free peritoneal gas indicating septic peritonitis if there is no recent history of laparotomy or abdominal puncture. Perforation of the gastrointestinal tract is the top differential either due to a foreign body, ulceration or less likely neoplasia. An mesenteric abscess is a potential but considered less likely.

HOSPITAL NAME

Ahwatukee
Commons VH

The roundish soft tissue structure in the caudal abdomen might present a focal granuloma or abscess formation.

REFERRING VET

Diagnostic celiotomy is advised.

Dr. Rebecca R.
Housley, DVM

INVOICE

13122

DATE

9/14/21



PATIENT

Rain Schreiber

SPECIES

Canine

BREED

German Shepherd
Mix

SEX

Female

AGE

2 Years 1 Month

INTERPRETED BY

Sebastian Schaub,
DVM Dr. med. vet.
DipECVDI

HOSPITAL NAME

Ahwatukee
Commons VH

REFERRING VET

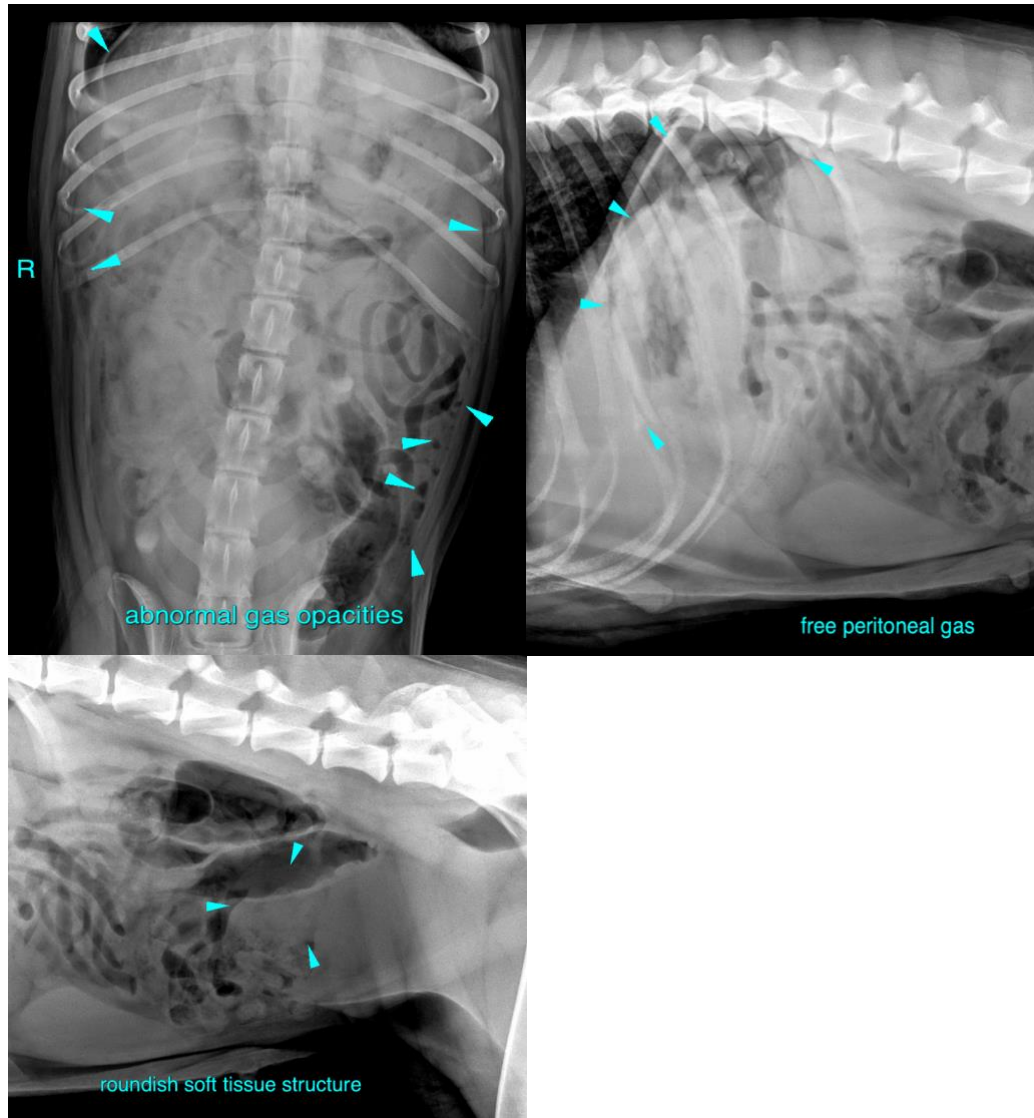
Dr. Rebecca R.
Housley, DVM

INVOICE

13122

DATE

9/14/21



The information and recommendations provided are based on the images presented by the referring veterinarian. No evaluation can be communicated regarding pathology that was not visible in the image/video clips provided.

Thank you for this referral. If the clinical or image interpretation does not parallel your findings or if I can be of any further assistance please contact me.

Sebastian Schaub, Sebastian Schaub, DVM, Dr. med. vet. DipECVDI
sebast.schaub@gmail.com



PATIENT

Rain Schreiber

SPECIES

Canine

BREED

German Shepherd
Mix

SEX

Female

AGE

2 Years 1 Month

INTERPRETED BY

Sebastian Schaub,
DVM Dr. med. vet.
DipECVDI

HOSPITAL NAME

Ahwatukee
Commons VH

REFERRING VET

Dr. Rebecca R.
Housley, DVM

INVOICE

13122

DATE

9/14/21