



PATIENT PRESENTING CLINICAL SIGNS

Oliver Moore History: Dx: collapsing trachea Lat/VD chest - cardiomegaly concerned collapsed cranial lung lobe bronchoalveolar pattern cranial lung appears consolidated
Abnormal PE/Chem/CBC/UA Results:

SPECIES RADIOGRAPHIC STUDY OF THE THORAX

Canine A complete set of radiographs of the thorax is provided for review.

BREED RADIOGRAPHIC FINDINGS

Poodle The body condition score is 8/9.
The surrounding bony structures are within normal limits.

SEX The extrathoracic soft tissues present homogeneous without abnormalities.

Female The size of the cardiac silhouette is accentuated a significant amount of pericardial fat. The pulmonary vasculature is within normal limits.

AGE The cranial mediastinum presents the expected soft tissue opacity. The mediastinal width is less than twice the width of the vertebral column at the same level.

6 Years 11 Months The trachea is normal in diameter and presents the anticipated course. The luminal outline of the trachea is smooth.

INTERPRETED BY The bronchial tree presents with thin walls and tapers uniformly towards the periphery as expected.

Sebastian Schaub, DVM Dr. med. vet. DipECVDI The lung parenchyma presents the expected architecture and opacity; the intrapulmonary vascular branching is seen up to the third order lung vessels.

HOSPITAL NAME The diaphragm is well delineated with even surface and the expected mild cranial bulging of the diaphragmatic cupola.

Loving Care VH

RADIOGRAPHIC DIAGNOSIS

REFERRING VET • Obesity

Kristie Steele **INTERPRETATION OF THE FINDINGS & FURTHER RECOMMENDATIONS**

INVOICE The main finding of the current radiographic study is the obesity of the patient. In the current set of radiographs no tracheal collapse is appreciated – in case of strong clinical suspicion of tracheal collapse either a fluoroscopy or tracheoscopy can be used to screen for tracheal collapse.

13100

Weight contral appears beneficial as well.

DATE

9/14/21



PATIENT

Oliver Moore

SPECIES

Canine

BREED

Poodle

SEX

Female

AGE

6 Years 11 Months

INTERPRETED BY

Sebastian Schaub,
DVM Dr. med. vet.
DipECVDI

HOSPITAL NAME

Loving Care VH

REFERRING VET

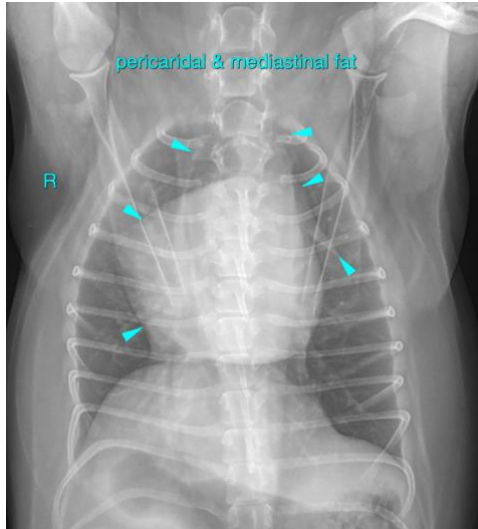
Kristie Steele

INVOICE

13100

DATE

9/14/21



The information and recommendations provided are based on the images presented by the referring veterinarian. No evaluation can be communicated regarding pathology that was not visible in the image/video clips provided.

Thank you for this referral. If the clinical or image interpretation does not parallel your findings or if I can be of any further assistance please contact me.

Sebastian Schaub, Sebastian Schaub, DVM, Dr. med. vet. DipECVDI
sebast.schaub@gmail.com