



PATIENT PRESENTING CLINICAL SIGNS

Nipsee Few History: Patient presented on 09/13/21 with concerns of not defecating as much since being on Purina Pro Plan HA. Owner mentioned that Patient eats grass all of the time.
Abnormal PE/Chem/CBC/UA Results:

SPECIES RADIOGRAPHIC STUDY OF THE ABDOMEN

Canine
Radiographs of the abdomen in two imaging planes are provided for review.

BREED RADIOGRAPHIC FINDINGS

Labrador Mix Multifocal mild spondylosis formation is present along the lumbar spine.

SEX Radiopaque suture material is seen level with the ventral abdominal wall and in the region of the ovaries and cervix. Three linear structures, presenting the same radiopacity like the suture material are seen in the cranial abdomen – suspect displaced suture material.

Spayed Female
The liver is appropriate in position, size and presents uniform opacity.

AGE The spleen is prominent.

8 Years 10 Months Both kidneys are seen and present with normal size, shape, delineation and opacity. The urinary bladder is in its anticipated position. No radiopaque calculi are noted throughout the upper and lower urinary tract.

INTERPRETED BY The stomach is in its anticipated position and presents normal content.

Sebastian Schaub, DVM Dr. med. vet. DipECVDI The small intestinal loops are of even diameter and non-dilated, a small amount of gas is seen within the small intestinal loops and considered within normal limits.

HOSPITAL NAME The colon is seen in the expected position and empty but a mild amount of gas and feces.

Ahwatukee Commons VH **RADIOGRAPHIC DIAGNOSIS**

- REFERRING VET**
- Splenomegaly
 - Empty colon
 - Spondylosis deformans lumbar spine

Dr. Linda R. Elliot **INTERPRETATION OF THE FINDINGS & FURTHER RECOMMENDATIONS**

INVOICE The splenomegaly represents likely a normal anatomical variant. If there is suspicion for diffuse infiltrative disease (e.g. splenitis, round cell tumor) ultrasound guided FNA sampling is recommended.

13084 The gastrointestinal tract presents without abnormalities. There are no signs for obstruction or constipation.

DATE

9/14/21



PATIENT

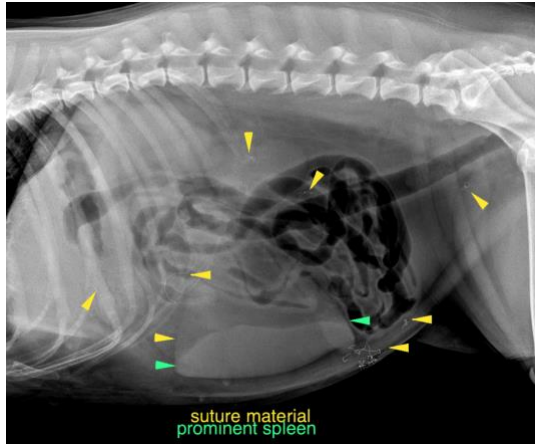
Nipsee Few

SPECIES

Canine

BREED

Labrador Mix



SEX

Spayed Female

AGE

8 Years 10 Months

The information and recommendations provided are based on the images presented by the referring veterinarian. No evaluation can be communicated regarding pathology that was not visible in the image/video clips provided.

Thank you for this referral. If the clinical or image interpretation does not parallel your findings or if I can be of any further assistance please contact me.

Sebastian Schaub, Sebastian Schaub, DVM, Dr. med. vet. DipECVDI
sebast.schaub@gmail.com

INTERPRETED BY

Sebastian Schaub,
DVM Dr. med. vet.
DipECVDI

HOSPITAL NAME

Ahwatukee
Commons VH

REFERRING VET

Dr. Linda R. Elliot

INVOICE

13084

DATE

9/14/21