



PATIENT PRESENTING CLINICAL SIGNS

Esther LeGrand
History: green nasal discharge from right nostril
Abnormal PE/Chem/CBC/UA Results:

SPECIES COMPUTED TOMOGRAPHIC STUDY OF THE SKULL

Canine A high resolution plain CT study of the viscerocranium is provided for review.

COMPUTED TOMOGRAPHIC FINDINGS

BREED

Collie
The pictured parts of the dentition are complete. Triadan 208 presents a moderate periapical widening of the periodontal space with perforation of the lateral cortex of the alveolar crest of the mesial and distal tooth root.

SEX

Spayed Female
The nasal cavity presents the expected aerated spaces between thin & even conchae and turbinates with smooth mucosal lining.

COMPUTED TOMOGRAPHIC DIAGNOSIS

AGE

9 Years

- Periapical abscess formation 208
- Structural normal nasal cavity

INTERPRETATION OF THE FINDINGS & FURTHER RECOMMENDATIONS

INTERPRETED BY

Sebastian Schaub,
DVM Dr. med. vet.
DipECVDI
The current CT study of the viscerocranium presents without abnormalities of the nasal cavity. There are no signs for rhinitis, foreign body or malignant disease. Recommend rhinoscopy with biopsy to rule in/out non-specific rhinitis.

HOSPITAL NAME

Cranberry Holistic PC

REFERRING VET

Cynthia Maro

INVOICE

13088

DATE

9/14/21



PATIENT

Esther LeGrand

SPECIES

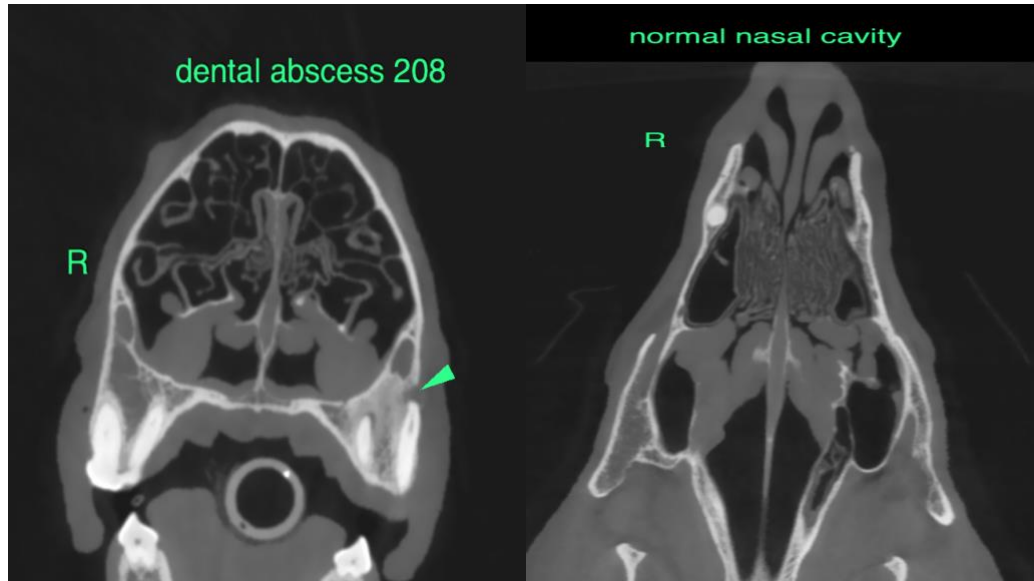
Canine

BREED

Collie

SEX

Spayed Female



AGE

9 Years

The information and recommendations provided are based on the images presented by the referring veterinarian. No evaluation can be communicated regarding pathology that was not visible in the image/video clips provided.

INTERPRETED BY

Sebastian Schaub,
DVM Dr. med. vet.
DipECVDI

Thank you for this referral. If the clinical or image interpretation does not parallel your findings or if I can be of any further assistance please contact me.

Sebastian Schaub, Sebastian Schaub, DVM, Dr. med. vet. DipECVDI
sebast.schaub@gmail.com

HOSPITAL NAME

Cranberry Holistic PC

REFERRING VET

Cynthia Maro

INVOICE

13088

DATE

9/14/21