



PATIENT PRESENTING CLINICAL SIGNS

Liberty Hamilton History: Patient has showed toe touching on Left hind, nsaid's not helping
Abnormal PE/Chem/CBC/UA Results:

SPECIES RADIOGRAPHIC STUDY OF THE STIFLE JOINTS

Canine A complete set of radiographs of the stifle joints is provided for review.

RADIOGRAPHIC FINDINGS

BREED

Bulldog The osseous and surrounding soft tissue structures of the right stifle joint are within normal limits.

SEX

Female The left stifle joint presents a moderate intracapsular soft tissue swelling displacing the infrapatellar fat-pad cranially and the fascial plane caudally. The periarticular bones of the left stifle joint present mild osteophyte new bone formation. The tibial intercondyl eminence is in a cranial position relative to the most distal aspect of the femoral condyles. Moderate osseous caudal elongation of the tibial plateau is visible.

AGE

4 Years

- Mild degenerative osteoarthritis left stifle joint with moderate caudal elongation of the tibial plateau
- Cranial tibial subluxation
- Moderate articular swelling left stifle joint
- Normal right stifle joint

INTERPRETED BY

Sebastian Schaub,
DVM Dr. med. vet.
DipECVDI

INTERPRETATION OF THE FINDINGS & FURTHER RECOMMENDATIONS

The radiographic study is consistent with left sided chronic degenerative osteoarthritis with concomitant joint effusion . Due to failure of the cranial cruciate ligament ± meniscal disease.

HOSPITAL NAME

Rockaway AH

A positive drawer sign or tibial compression test under general anesthesia can be used to confirm the diagnosis and surgical intervention – a correction osteotomy technique would be ideal – would be beneficial.

REFERRING VET

Dr. Maniar

INVOICE

13065

DATE

9/13/21



PATIENT

Liberty Hamilton

SPECIES

Canine

BREED

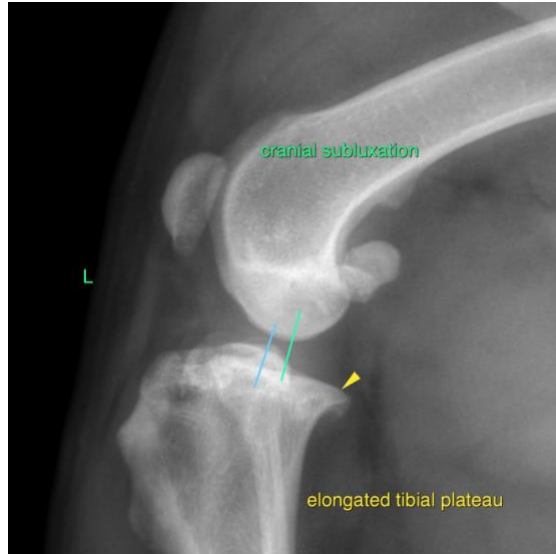
Bulldog

SEX

Female

AGE

4 Years



The information and recommendations provided are based on the images presented by the referring veterinarian. No evaluation can be communicated regarding pathology that was not visible in the image/video clips provided.

Thank you for this referral. If the clinical or image interpretation does not parallel your findings or if I can be of any further assistance please contact me.

INTERPRETED BY

Sebastian Schaub, Sebastian Schaub, DVM, Dr. med. vet. DipECVDI
sebast.schaub@gmail.com

Sebastian Schaub,
DVM Dr. med. vet.
DipECVDI

HOSPITAL NAME

Rockaway AH

REFERRING VET

Dr. Maniar

INVOICE

13065

DATE

9/13/21