



**PATIENT PRESENTING CLINICAL SIGNS**

Roan Southwell History: Acute onset Vomit for 1 and a half days, bloody diarrhea.  
Abnormal PE/Chem/CBC/UA Results:

**SPECIES RADIOGRAPHIC STUDY OF THE ABOMEN**

Canine A complete set of radiographs of the abdomen is provided for review.

**RADIOGRAPHIC FINDINGS**

**BREED**

Terrier Mix The surrounding bony structures are within normal limits.

No abnormalities of the extraabdominal soft tissues are noted. The abdominal wall is smooth and thin.

**SEX**

The serosal detail is maintained throughout the peritoneal and retroperitoneal space.

Neutered Male

The liver is appropriate in position, size and presents uniform opacity.

**AGE**

2 Years 9 Months

The splenic head is in the anticipated position and within normal limits for size and opacity. The splenic body and tail are considered normal for position, size, shape and opacity.

Both kidneys are seen and present with normal size, shape, delineation and opacity. The urinary bladder is in its anticipated position. No radiopaque calculi are noted throughout the upper and lower urinary tract.

**INTERPRETED BY**

Sebastian Schaub,  
DVM Dr. med. vet.  
DipECVDI

The stomach is in its anticipated position and empty.

The small intestinal loops are of even diameter and non-dilated, a small amount of gas is seen within the small intestinal loops and considered within normal limits.

**HOSPITAL NAME**

DTLA Vets

The colon is seen in the expected position, moderately distended by gas and otherwise empty.

**RADIOGRAPHIC DIAGNOSIS**

**REFERRING VET**

Dr. Castaneda

- Empty gastrointestinal tract
- Empty colon

**INTERPRETATION OF THE FINDINGS & FURTHER RECOMMENDATIONS**

**INVOICE**

13032

The empty gastrointestinal tract – including the colon – in combination with the given clinical signs is suggestive for acute hemorrhagic diarrhea syndrome. There is no evidence of radiopaque foreign material or signs for gastrointestinal mechanical obstruction.

**DATE**

9/10/21



**PATIENT**

Roan Southwell

**SPECIES**

Canine

**BREED**

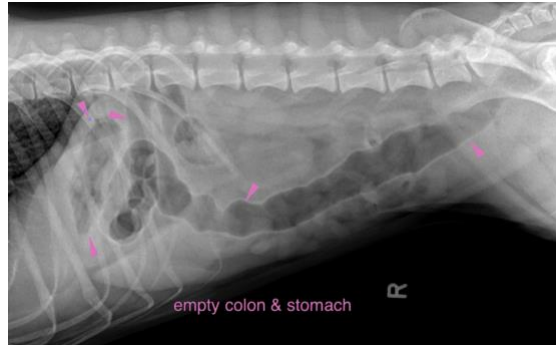
Terrier Mix

**SEX**

Neutered Male

**AGE**

2 Years 9 Months



**The information and recommendations provided are based on the images presented by the referring veterinarian. No evaluation can be communicated regarding pathology that was not visible in the image/video clips provided.**

Thank you for this referral. If the clinical or image interpretation does not parallel your findings or if I can be of any further assistance please contact me.

**Sebastian Schaub**, Sebastian Schaub, DVM, Dr. med. vet. DipECVDI  
sebast.schaub@gmail.com

**INTERPRETED BY**

Sebastian Schaub,  
DVM Dr. med. vet.  
DipECVDI

**HOSPITAL NAME**

DTLA Vets

**REFERRING VET**

Dr. Castaneda

**INVOICE**

13032

**DATE**

9/10/21