



PATIENT PRESENTING CLINICAL SIGNS

Chico Wilson History: P presented for evaluation of acute onset of lameness on the right hindlimb. O notes that the P does not appear painful and that it started following jumping from stairs onto the bed. PE shows intermittent non-weight bearing to toe-touching lameness on the right hindlimb. Subjectively positive cranial drawer sign w/ minimal discomfort of swelling on palpation.

SPECIES

Canine

RADIOGRAPHIC STUDY OF THE STIFLE JOINTS

BREED

A complete set of radiographs of the stifle joints is provided for review.

Pomeranian Mix

RADIOGRAPHIC FINDINGS

SEX

At the lateral aspect of the right tibia, level with the mid diaphysis, a convex shaped soft tissue swelling is seen measuring 10 mm in size.

Neutered Male

The left stifle joint presents a mild intracapsular soft tissue swelling, distorting the infrapatellar fat-pad cranially.

AGE

14.5 Years

The right stifle joint is within normal limits.
The osseous margins of both stifle joints are smooth.

INTERPRETED BY

The patella bilaterally is in situ.

Sebastian Schaub,
DVM Dr. med. vet.
DipECVDI

RADIOGRAPHIC DIAGNOSIS

- Possible mild intraarticular swelling left stifle joint
- Soft tissue swelling lateral aspect right tibia

HOSPITAL NAME

Boca Park AH

INTERPRETATION OF THE FINDINGS & FURTHER RECOMMENDATIONS

The current set of radiographs of the stifle joints presents with possible mild articular swelling of the left stifle joint – degenerative, traumatic, inflammatory; due to the lack of clinical signs the clinical relevance is questionable.

REFERRING VET

Dr. Tifanie Silver

The right stifle joint presents without abnormalities. Check clinically for signs of patellar luxation as well.

INVOICE

13057

The cutaneous swelling at the lateral aspect of the right crus can represent inflammation, benign or malignant neoplasia.

DATE

9/10/21



PATIENT

Chico Wilson

SPECIES

Canine

BREED

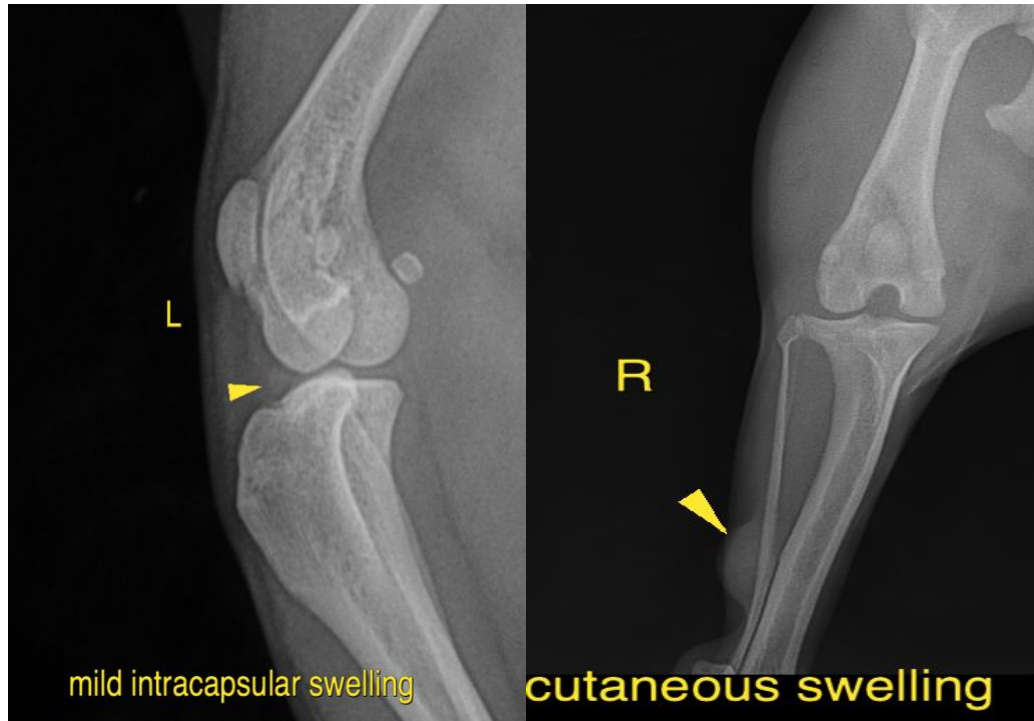
Pomeranian Mix

SEX

Neutered Male

AGE

14.5 Years



INTERPRETED BY

Sebastian Schaub,
DVM Dr. med. vet.
DipECVDI

The information and recommendations provided are based on the images presented by the referring veterinarian. No evaluation can be communicated regarding pathology that was not visible in the image/video clips provided.

Thank you for this referral. If the clinical or image interpretation does not parallel your findings or if I can be of any further assistance please contact me.

HOSPITAL NAME

Boca Park AH

Sebastian Schaub, Sebastian Schaub, DVM, Dr. med. vet. DipECVDI
sebast.schaub@gmail.com

REFERRING VET

Dr. Tifanie Silver

INVOICE

13057

DATE

9/10/21