



PATIENT PRESENTING CLINICAL SIGNS

Mo Albury Presented to rdvm for straining to urinate. Abdominal ultrasound performed and found left kidney mass but bladder and prostate normal. Currently not straining. No cytology done. Abnormal PE/Chem/CBC/UA Results: BW normal other than mild ALT elevation.

SPECIES COMPUTED TOMOGRAPHY OF THE THORAX AND ABDOMEN

Canine A high resolution pre- and post-contrast CT study of the abdomen and a post-contrast CT study of the thorax are provided for review.

BREED COMPUTED TOMOGRAPHIC FINDINGS

German Shepherd Thorax

Multifocal mild spondylosis formation is seen along the thoracic spine.

SEX The sternal, cranial mediastinal and tracheobronchial lymph nodes are small elongated with a normal short-to-long-axis-ratio is < 0.5, the attenuation and contrast enhancement pattern is uniform and considered within normal limits.

Neutered Male

The cardiovascular structures are within normal limits.

AGE The bronchial tree presents with regular branching and tapers uniformly towards the periphery as expected, the bronchial walls are thin and smooth. The bronchus-to-artery ratio is within normal limits.

6.5 Years

The lung parenchyma presents a generalized decreased volume and subsequent mild to moderate ground glass attenuation pattern of the lung parenchyma - most pronounced in the caudodorsal dependent aspects of the lung parenchyma. Mild mineralization of peripheral arteries of the right caudal lung lobe and the accessory lung lobe is seen.

INTERPRETED BY

Sebastian Schaub, DVM
Dr. med. vet. DipECVDI

Small incidental gas pockets are seen within the esophageal lumen, there is no evidence of abnormal dilation.

HOSPITAL NAME Abdomen

Mobile Pet Imaging

The serosal fat presents normal attenuation behavior. There is no evidence of peritoneal effusion or peritonitis.

REFERRING VET

Meaux

The right kidney presents within normal limits for size, shape and organ architecture with mild pinpoint mineralization of the renal parenchyma.

Protruding from the lateral aspect of the left kidney, an irregular shaped, soft tissue attenuating and heterogeneous contrast enhancing mass is seen, measuring 7.3 x 5.0 x 6.2 cm in size with loss of the local normal renal architecture. Post contrast administration, the left renal mass has a mild heterogeneous contrast enhancement pattern.

INVOICE

53892

Both kidneys present a physiological pyelogram.

The adrenal glands are within normal limits for size, shape and organ architecture.

DATE

9-1-22

Both liver and spleen present with normal shape, even surface, uniformly attenuating parenchyma and homogeneous contrast enhancement, unremarkable.

The pancreas is evenly contoured, the pancreatic parenchyma is homogeneous and presents uniform contrast enhancement.



PATIENT The position, delineation, wall and content of the gastrointestinal tract are considered within normal limits throughout.

Mo Albury The lumbar spine presents multifocal moderate spondylosis formation. Both coxofemoral joints present moderate osteophyte new bone formation.

SPECIES **COMPUTED TOMOGRAPHIC DIAGNOSIS**

- Canine
- Left renal soft tissue mass
 - Mild nephrocalcinosis right kidney
 - Mild dystrophic mineralization peripheral pulmonary arteries right caudal lung lobe & accessory lung lobe
- BREED
- Dystelectasis of the lung parenchyma – secondary to general anesthesia
- German Shepherd
- Degenerative osteoarthritis coxofemoral joints bilaterally
 - Spondylosis deformans
 - No evidence of pulmonary metastatic disease

SEX

Neutered Male

INTERPRETATION OF THE FINDINGS & FURTHER RECOMMENDATIONS

AGE

6.5 Years

The left renal mass is compatible with primary renal neoplasia – such as renal cell carcinoma, hemangiosarcoma, other. Complete surgical excision of the renal mass by left sided nephrectomy is considered feasible.

If the renal mass is explaining the described clinical signs is unclear, and concomitant pathology such as detrusor-sphincter-dyssynergy or urethral mural swelling might be a possibilities as well.

INTERPRETED BY

Sebastian Schaub, DVM
Dr. med. vet. DipECVDI

The mineralization of the pulmonary arteries can be caused by preceding or ongoing parasitic infection, such as Angiostrongylus or Dirofilaria. Testing for potential infection following the guidelines of the “American Heartworm Society” <https://www.heartwormsociety.org> is recommended.

HOSPITAL NAME

Mobile Pet Imaging

REFERRING VET

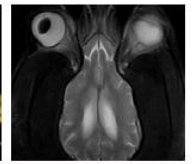
Meaux

INVOICE

53892

DATE

9-1-22



PATIENT

Mo Albury

SPECIES

Canine

BREED

German Shepherd

SEX

Neutered Male

AGE

6.5 Years

INTERPRETED BY

Sebastian Schaub, DVM
Dr. med. vet. DipECVDI

HOSPITAL NAME

Mobile Pet Imaging

REFERRING VET

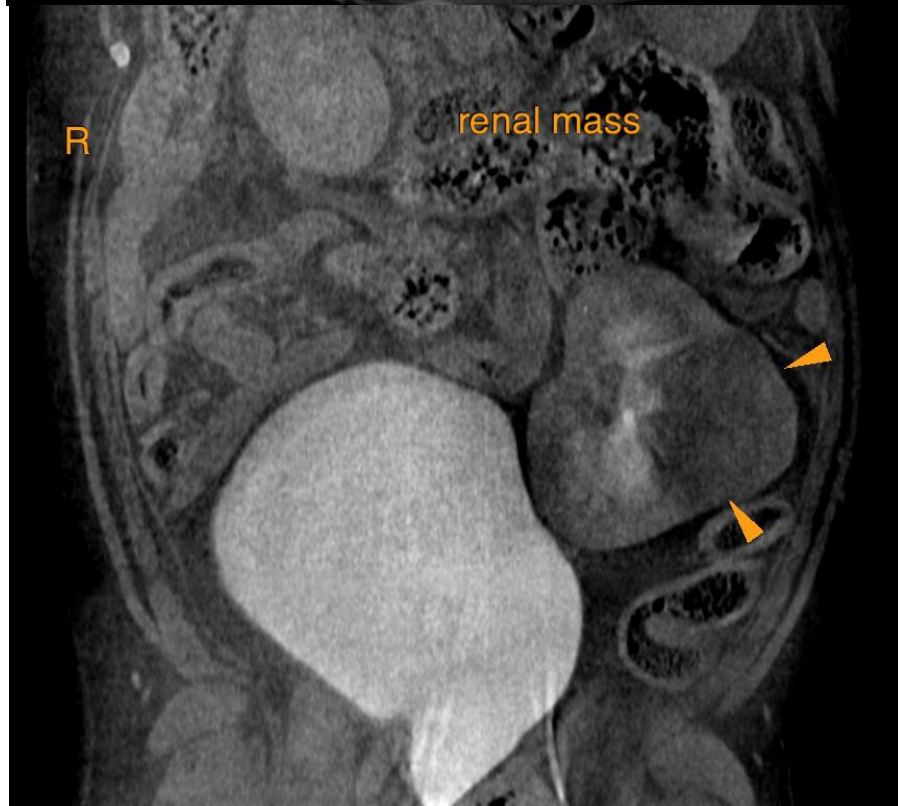
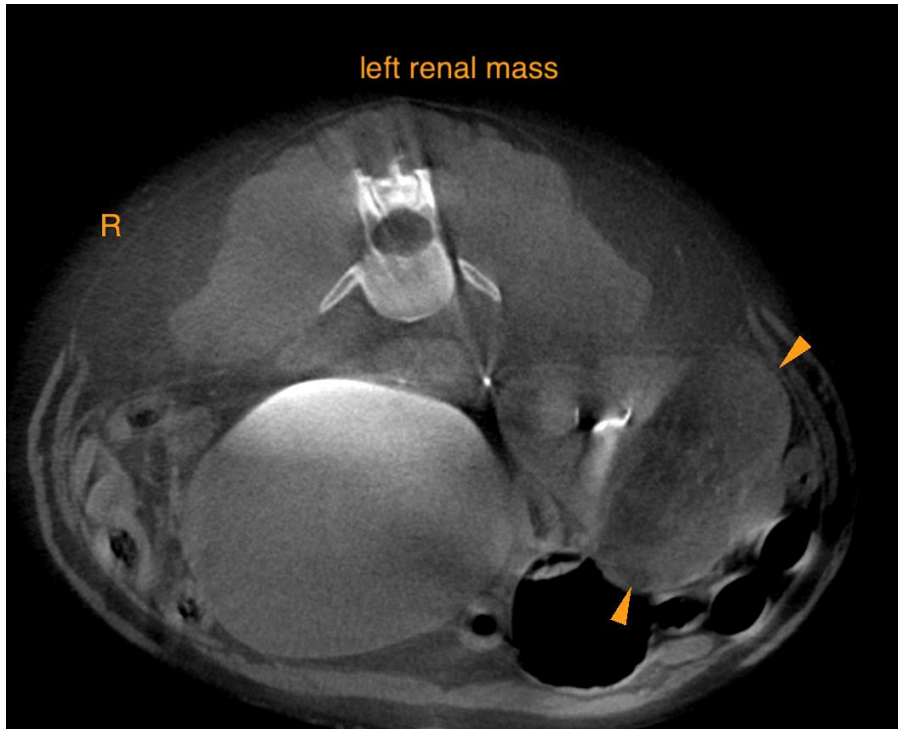
Meaux

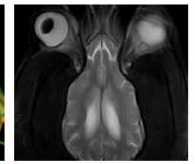
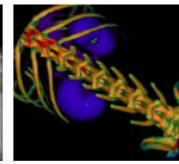
INVOICE

53892

DATE

9-1-22





PATIENT

Mo Albury

SPECIES

Canine

BREED

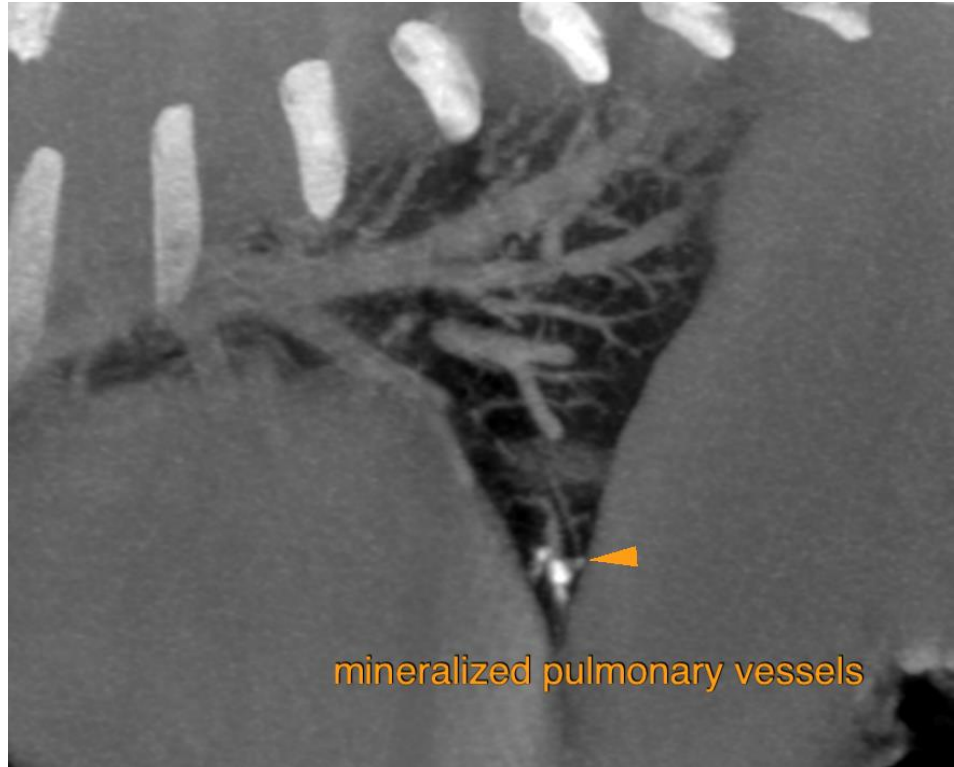German Shepherd

SEX

Neutered Male

AGE

6.5 Years



INTERPRETED BY

Sebastian Schaub, DVM
Dr. med. vet. DipECVDI

The information and recommendations provided are based on the images presented by the referring veterinarian/sonographer. No evaluation can be communicated regarding pathology that was not visible in the image/video clips provided.

HOSPITAL NAME

Mobile Pet Imaging

Thank you for this referral. If the clinical or image interpretation does not parallel your findings or if I can be of any further assistance please contact me.

REFERRING VET

Meaux

Sebastian Schaub, Sebastian Schaub, DVM, Dr. med. vet. DipECVDI
sebast.schaub@gmail.com

INVOICE

53892

DATE

9-1-22