



PATIENT PRESENTING CLINICAL SIGNS

Flash Silva Paraparesis, deep pain negative. Diarrhea
 Abnormal PE/Chem/CBC/UA Results: Open wound Right gluteal area.

SPECIES COMPUTED TOMOGRAPHY OF THE THORACIC & LUMBAR SPINE

Canine A high resolution pre- and post-contrast CT study of the thoracic & lumbar spine is provided for review.

COMPUTED TOMOGRAPHIC FINDINGS

THE LAST RIB BEARING VERTEBRA IS COUNTED AS T13.

Mixed The osseous and soft tissue structures of the thoracic spine are within normal limits.

SEX The intervertebral disc space L3/L4 is moderately narrowed. Level with the intervertebral disc space L3/L4, heterogeneous mineralized material is seen in the right lateral and ventral aspect of the vertebral canal, occupying approximately up to 70% of the cross-sectional area of the vertebral canal at the same level. The hypoattenuating material is extending cranially up to the level of the cranial vertebral endplate L3 and caudally over the cranial third of the vertebral body of L4. The dural tube L3/L4 is deviated to the left and compressed.

Neutered Male

AGE The intervertebral discs L2/L3 and L6/L7 are mildly protruding into the vertebral canal, distorting the ventral epidural space.

5 Years Mineralization of the intervertebral discs T10/T11, L4/L5-L6/L7 is appreciated.

COMPUTED TOMOGRAPHIC DIAGNOSIS

INTERPRETED BY

- Intervertebral disc extrusion L3/L4 with compressive myelopathy
- Mild intervertebral disc protrusion L2/L3 and L6/L7 without compressive myelopathy
- Multifocal chondroid disc degeneration

Sebastian Schaub, DVM
 Dr. med. vet. DipECVDI

HOSPITAL NAME

INTERPRETATION OF THE FINDINGS & FURTHER RECOMMENDATIONS

Mobile Pet Imaging

The intervertebral disc extrusion L3/L4 from the right side is a plausible explanation for the presenting clinical signs and surgical decompression is advised.

REFERRING VET

Meaux

INVOICE

53899

DATE

9-1-22



PATIENT

Flash Silva

SPECIES

Canine

BREED

Mixed

SEX

Neutered Male

AGE

5 Years

INTERPRETED BY

Sebastian Schaub, DVM
Dr. med. vet. DipECVDI

HOSPITAL NAME

Mobile Pet Imaging

REFERRING VET

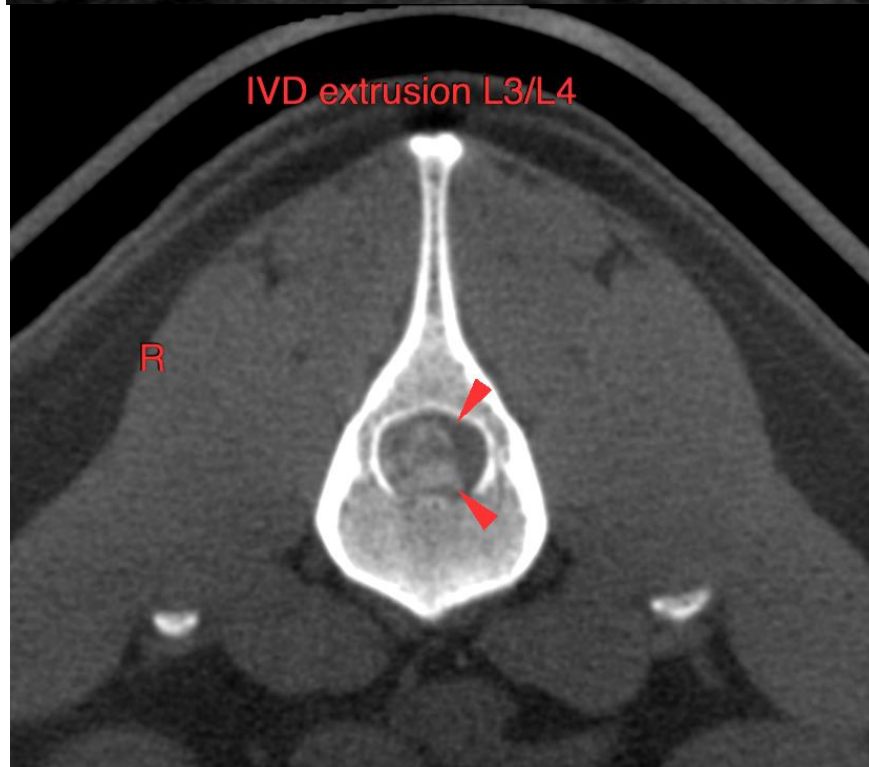
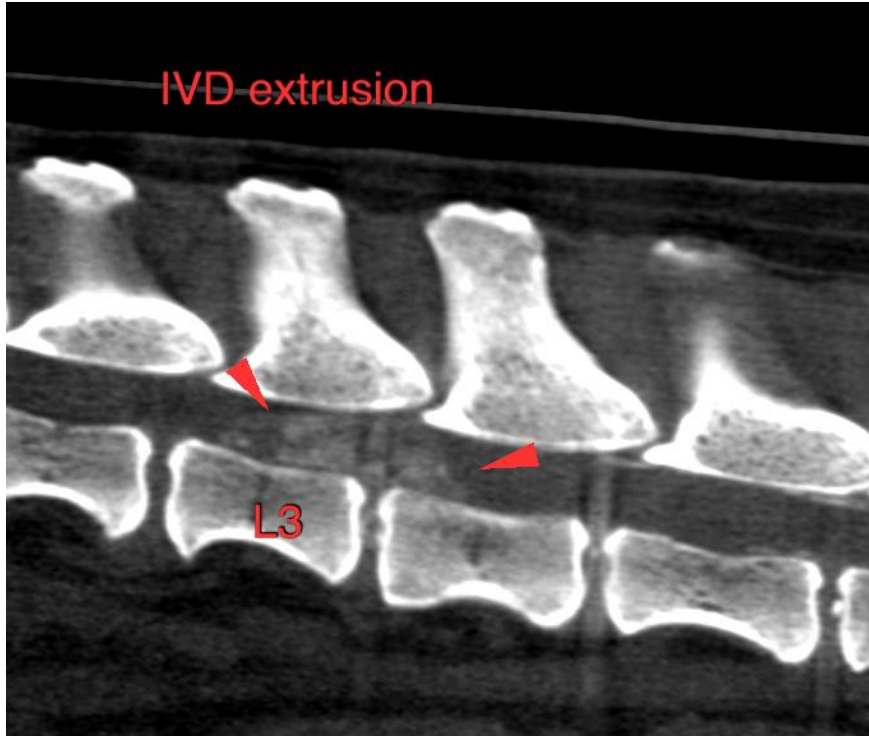
Meaux

INVOICE

53899

DATE

9-1-22





PATIENT The information and recommendations provided are based on the images presented by the referring veterinarian/sonographer. No evaluation can be communicated regarding pathology that was not visible in the image/video clips provided.

Flash Silva

SPECIES

Thank you for this referral. If the clinical or image interpretation does not parallel your findings or if I can be of any further assistance please contact me.

Canine

Sebastian Schaub, Sebastian Schaub, DVM, Dr. med. vet. DipECVDI
sebast.schaub@gmail.com

BREED

Mixed

SEX

Neutered Male

AGE

5 Years

INTERPRETED BY

Sebastian Schaub, DVM
Dr. med. vet. DipECVDI

HOSPITAL NAME

Mobile Pet Imaging

REFERRING VET

Meaux

INVOICE

53899

DATE

9-1-22