



PATIENT PRESENTING CLINICAL SIGNS

Ace Bloor Assessment of ventral aspect of tongue shows proliferative lesion around frenulum, and ventral aspect of the tongue very hard. Swelling on right ventral neck.

SPECIES COMPUTED TOMOGRAPHY OF THE SKULL & NECK

Canine A high resolution pre- and post-contrast CT study of the skull including the neck is provided for review.

BREED COMPUTED TOMOGRAPHIC FINDINGS

Labrador Retriever The pictured parts of the dentition are complete and unremarkable in all jaw quadrants.

SEX

Male Entire The sublingual tissue, in the region of the frenulum is swollen and merges with the borders of the tongue, the contrast enhancement pattern of the soft tissues ventral to the tongue appears mildly heterogeneous with a hypoattenuating roundish zone level with the mandibular M1.

AGE

8 The nasal cavity presents the expected aerated spaces between thin & even conchae and turbinates with smooth mucosal lining.

INTERPRETED BY

Sebastian Schaub, DVM Dr. med. vet. DipECVDI Both temporomandibular joints present congruent joint spaces with even subchondral bone surfaces and are considered within normal limits.

HOSPITAL NAME

Myerscough Veterinary Group The external ear canals are within normal limits. The brain presents no deviation from normal anatomy and symmetry. The brain parenchyma is homogeneous and within normal limits for attenuation and distribution of contrast enhancement. The ventricular system is non-dilated and symmetric.

REFERRING VET

- Ros McKenzie
- The subcutaneous tissue along the caudoventral aspect of the skull/cranial aspect of the neck presents a mild to moderate swelling with moderate fat-stranding of the subcutaneous fat.
 - Soft tissue swelling floor of oral cavity, region of the frenulum of the tongue with possible central cavitory lesion
 - Lymphadenopathy with small intraparenchymal cavitory lesions medial retropharyngeal lymph nodes bilaterally
 - Subcutaneous cellulitis along the submandibular region

INVOICE

53890 **INTERPRETATION OF THE FINDINGS & FURTHER RECOMMENDATIONS**

DATE

9-1-22 The medial retropharyngeal lymph nodes bilaterally are moderately enlarged and have a heterogeneous contrast enhancement pattern with multiple fluid attenuating roundish intraparenchymal regions, L>R. The sublingual swelling is not specific and assessment by CT is limited by border effacement with the overlying tongue and mild streak artefacts originating from the body of the mandibles. Inflammatory origin of the swelling is considered more likely with a possible small cavitory lesions level with the mandibular M1. Neoplastic transformation is a consideration as well but would expect more chronic (progressive) clinical signs. Ultrasound can be used to rule in/out cavitory lesion and screen for isoattenuating foreign material.



PATIENT

Ace Bloor

The cellulitis along the caudoventral aspect of the skull and the lymphadenopathy of the medial retropharyngeal lymph nodes is also increasing the odds for inflammatory origin with possible small abscesses within the medial retropharyngeal lymph nodes. Anyway, recommend FNA sampling as carcinoma might cause cavitary lesions within the lymph nodes as well.

SPECIES

Canine

BREED

Labrador Retriever

SEX

Male Entire

AGE

8

INTERPRETED BY

Sebastian Schaub, DVM
Dr. med. vet. DipECVDI

HOSPITAL NAME

Myerscough
Veterinary Group

REFERRING VET

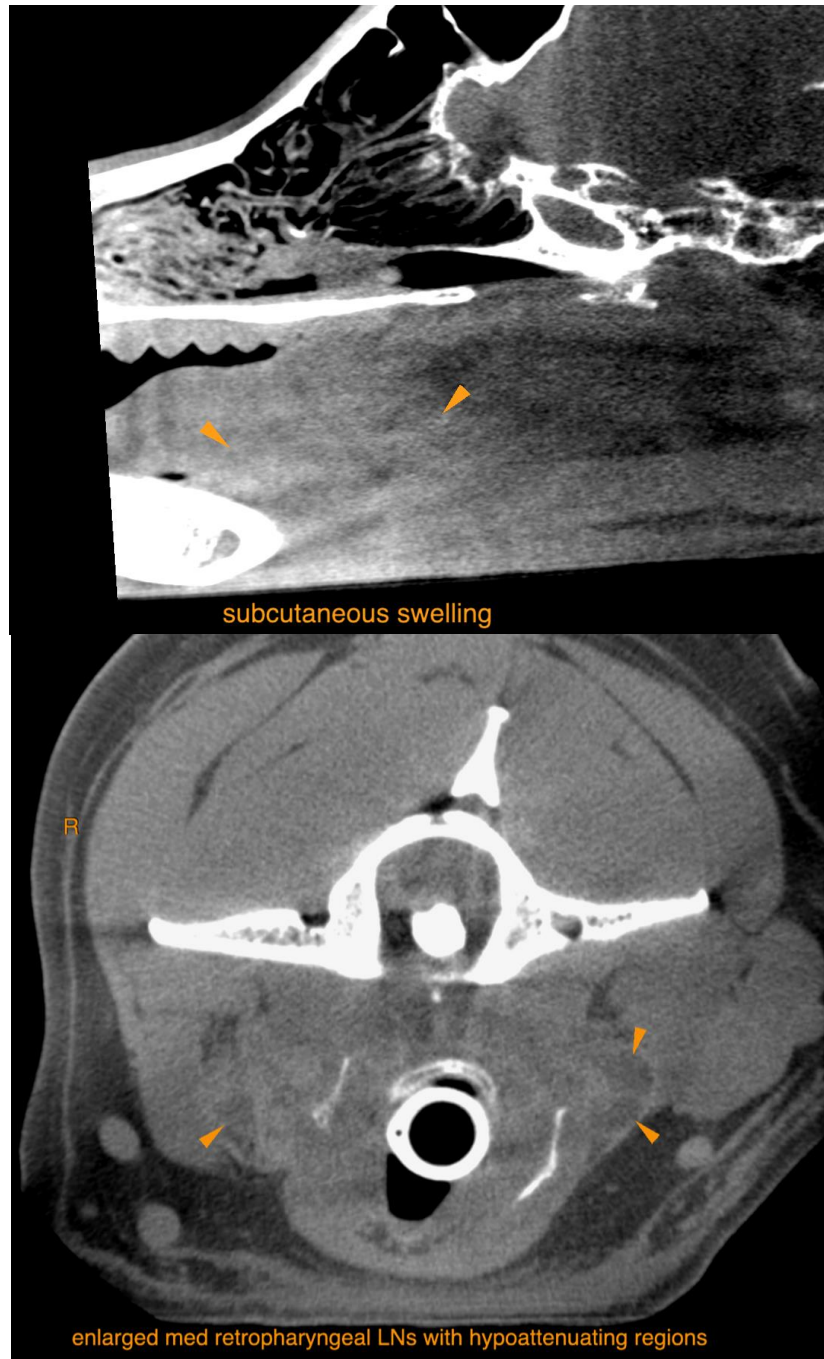
Ros McKenzie

INVOICE

53890

DATE

9-1-22





PATIENT

Ace Bloor

SPECIES

Canine

BREED

Labrador Retriever

SEX

Male Entire

AGE

8

INTERPRETED BY

Sebastian Schaub, DVM
Dr. med. vet. DipECVDI

HOSPITAL NAME

Myerscough
Veterinary Group

REFERRING VET

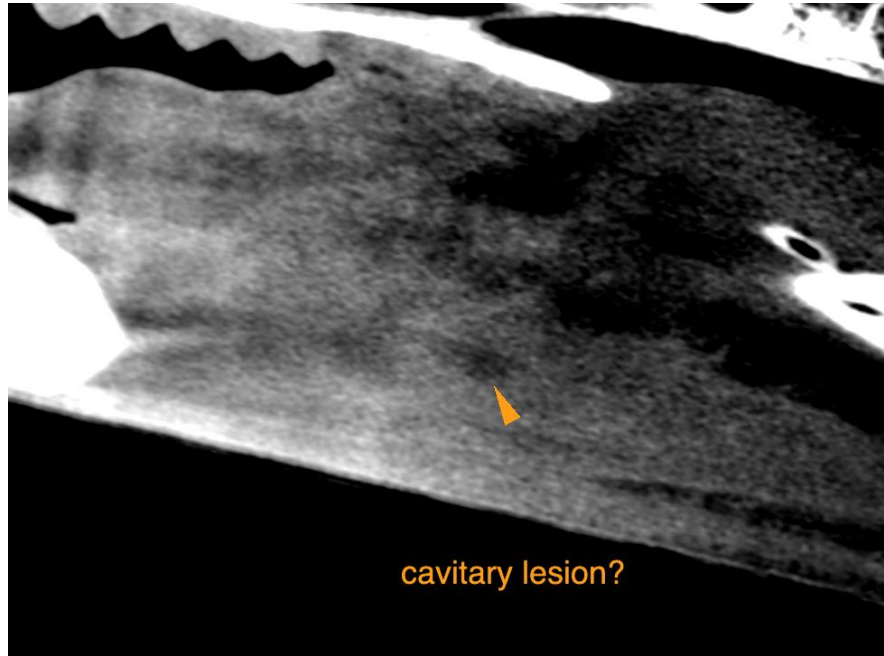Ros McKenzie

INVOICE

53890

DATE

9-1-22



The information and recommendations provided are based on the images presented by the referring veterinarian/sonographer. No evaluation can be communicated regarding pathology that was not visible in the image/video clips provided.

Thank you for this referral. If the clinical or image interpretation does not parallel your findings or if I can be of any further assistance please contact me.

Sebastian Schaub, Sebastian Schaub, DVM, Dr. med. vet. DipECVDI
sebast.schaub@gmail.com