



PATIENT

Abbey Mehreteab

PRESENTING CLINICAL SIGNS

Right hind leg possible ACL tear

SPECIES

Canine

RADIOGRAPHIC STUDY OF THE STIFLE JOINTS

Radiographs of the stifle joints in two orthogonal imaging planes are provided for review.

BREED

Basset Hound

RADIOGRAPHIC FINDINGS

The periarticular bones of the right stifle joint present moderate osteophyte new bone formation and there is a significant intracapsular soft tissue swelling of the right stifle joint, effacing the infrapatellar fat pad cranially and distorting the fascial plane caudally.

The periarticular bones of the left stifle joint present mild to moderate osteophyte new bone formation and a moderate intracapsular soft tissue swelling.

SEX

Female

RADIOGRAPHIC DIAGNOSIS

- Moderate degenerative osteoarthritis stifle joints bilaterally
- Articular swelling stifle joints bilaterally, R>L

AGE

13 Years

INTERPRETATION OF THE FINDINGS & FURTHER RECOMMENDATIONS

The radiographic study is consistent with bilateral chronic degenerative osteoarthritis with concomitant joint effusion of both stifle joints, R>L. The most-likely underlying cause is (partial) rupture of the cranial cruciate ligament ± meniscal disease.

INTERPRETED BY

Sebastian Schaub, DVM
Dr. med. vet. DipECVDI

A positive drawer sign or tibial compression test under general anesthesia can be used to confirm the diagnosis and surgical intervention of the clinically more conspicuous right stifle joint is considered beneficial. Surgical intervention of the left stifle joint may be considered as well after the post-operative recovery phase.

HOSPITAL NAME

Truscott Animal
Hospital

REFERRING VET

Dr. Medhat Meawad

INVOICE

53888

DATE

9-1-22



PATIENT

Abbey Mehreteab

SPECIES

Canine

BREED

Basset Hound

SEX

Female

AGE

13 Years

INTERPRETED BY

Sebastian Schaub, DVM
Dr. med. vet. DipECVDI

HOSPITAL NAME

Truscott Animal
Hospital

REFERRING VET

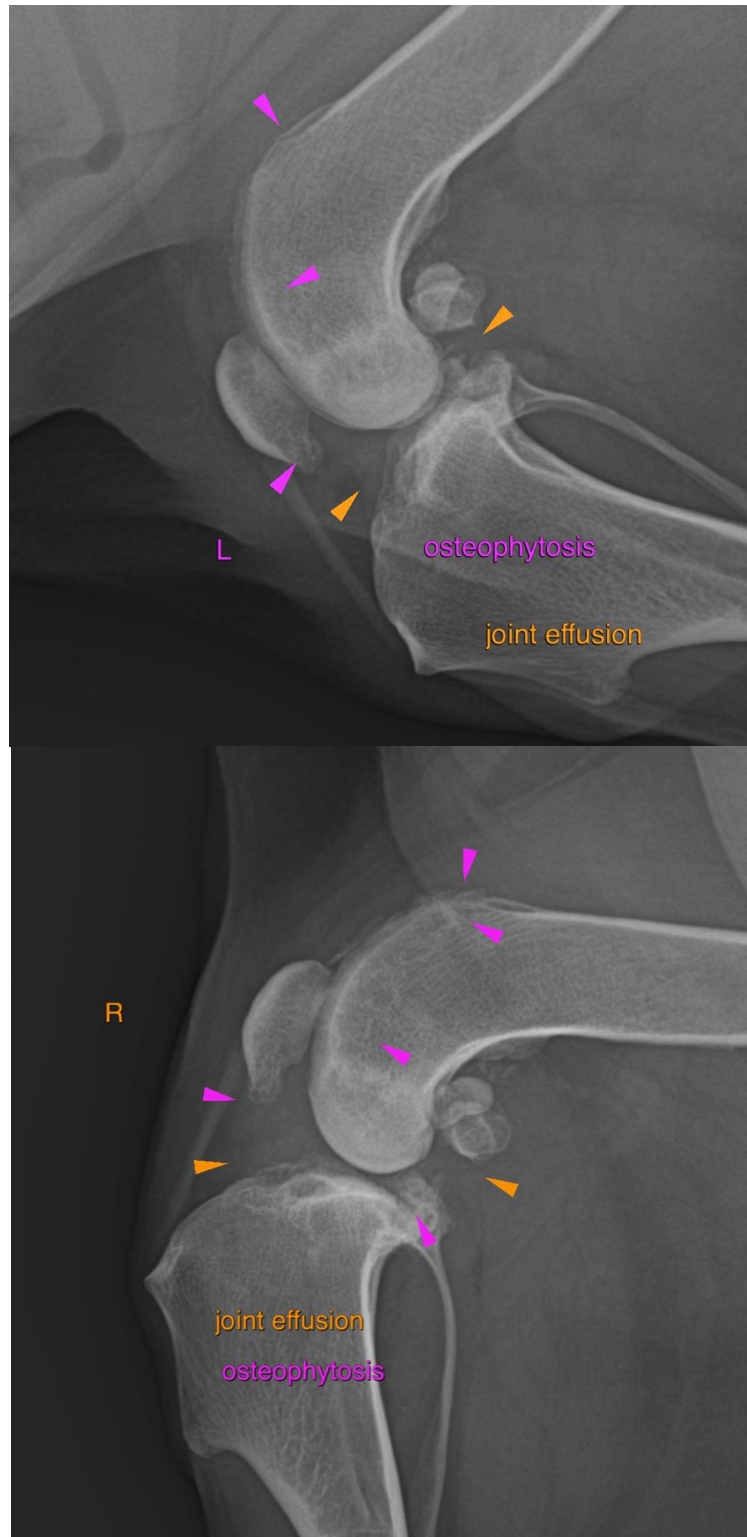
Dr. Medhat Meawad

INVOICE

53888

DATE

9-1-22





PATIENT

Abbey Mehreteab

The information and recommendations provided are based on the images presented by the referring veterinarian/sonographer. No evaluation can be communicated regarding pathology that was not visible in the image/video clips provided.

Thank you for this referral. If the clinical or image interpretation does not parallel your findings or if I can be of any further assistance please contact me.

SPECIES

Canine

Sebastian Schaub, Sebastian Schaub, DVM, Dr. med. vet. DipECVDI
sebast.schaub@gmail.com

BREED

Basset Hound

SEX

Female

AGE

13 Years

INTERPRETED BY

Sebastian Schaub, DVM
Dr. med. vet. DipECVDI

HOSPITAL NAME

Truscott Animal
Hospital

REFERRING VET

Dr. Medhat Meawad

INVOICE

53888

DATE

9-1-22