


PATIENT PRESENTING CLINICAL SIGNS

Luna Menegon Young dog with severe abdominal pain of 5 month duration. Pain localizes to right caudal abdomen - repeatable and severe. Eating well, no vomiting, possible mild R sided pelvic limb lameness. Normal blood work. No trauma. Possible linear material at PDJ seen on ultrasound. Possibly incompletely closed ileal wing growth plates on radiographs. CT to look for cause of marked abdominal pain, assess PDJ better, assess ileal wings.

Canine Abnormal PE/Chem/CBC/UA Results: Normal CBC & Chem Very pain abdomen (throughout - most notable right caudal abdomen) No lameness seen.

BREED COMPUTED TOMOGRAPHIC STUDY OF THE ABDOMEN

Bichon x A plain CT study of the abdomen in a bone and soft tissue reconstruction is provided for review.

SEX COMPUTED TOMOGRAPHIC FINDINGS

Spayed Female The serosal fat presents normal attenuation behavior. There is no evidence of peritoneal effusion or peritonitis. A separate left & right caudal vena cava of the pre-renal segment is appreciated.

AGE Both kidneys present within normal limits for size, shape and organ architecture.

3 Years The adrenal glands are within normal limits for size, shape and organ architecture.

Both liver and spleen present with normal shape, even surface, uniformly attenuating parenchyma.

INTERPRETED BY The pancreas is evenly contoured, the pancreatic parenchyma is homogeneous.

Sebastian Schaub, DVM Dr. med. vet. DipECVDI The position, delineation, wall and content of the gastrointestinal tract are considered within normal limits throughout.

HOSPITAL NAME The bony and surrounding soft tissue structures reveal no abnormalities - incomplete fusion of the apophysis of the iliac wing bilaterally is seen.

Animal Health Partners **COMPUTED TOMOGRAPHIC DIAGNOSIS**

- Double caudal vena cava, pre-renal segment - incidental anatomical variant

REFERRING VET INTERPRETATION OF THE FINDINGS & FURTHER RECOMMENDATIONS

Dr. Ashley Gold The CT study reveals no macromorphological abnormality that can explain the described clinical signs. There is no sign for inflammatory lesions or abnormal osseous changes.

INVOICE

44556

DATE

8/9/23



PATIENT

Luna Menegon

SPECIES

Canine

BREED

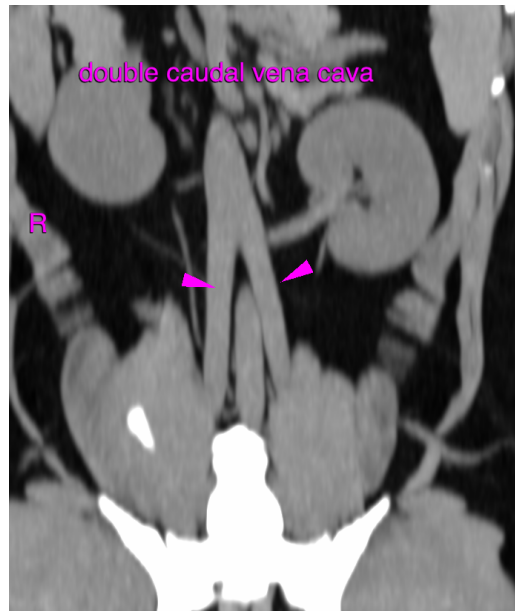
Bichon x

SEX

Spayed Female

AGE

3 Years



The information and recommendations provided are based on the images presented by the referring veterinarian. No evaluation can be communicated regarding pathology that was not visible in the image/video clips provided.

INTERPRETED BY

Sebastian Schaub,
DVM Dr. med. vet.
DipECVDI

Thank you for this referral. If the clinical or image interpretation does not parallel your findings or if I can be of any further assistance please contact me.

Sebastian Schaub, Sebastian Schaub, DVM, Dr. med. vet. DipECVDI
sebast.schaub@gmail.com

HOSPITAL NAME

Animal Health
Partners

REFERRING VET

Dr. Ashley Gold

INVOICE

44556

DATE

8/9/23