


PATIENT PRESENTING CLINICAL SIGNS

Hope Costa
 History (Subjective): Overall panting for 6 months, coughing for A 1 week, whooping cough like. every 30- 90 minutes, 1-2x day then stops. more if excited. Pants continuously at home. pu/pdGrade 4/9 mitral murmur band coarse. subjective sl purplish hue to tongue
 Abnormal PE/Chem/CBC/UA Results: in process

SPECIES

Canine

RADIOGRAPHIC STUDY OF THE THORAX

Radiographs of the thorax in three imaging planes are provided for review.

BREED

Maltese

RADIOGRAPHIC FINDINGS

The body condition score is 8-9/9.

SEX

Female

The surrounding bony structures are within normal limits.

The extrathoracic soft tissues present homogeneous without abnormalities.

The caudal contour of the cardiac silhouette is steep and the caudal cardiac waist is lost. The pulmonary vasculature is within normal limits.

AGE

13

The cranial mediastinum presents the expected soft tissue opacity. The mediastinal width is less than twice the width of the vertebral column at the same level.

INTERPRETED BY

Sebastian Schaub,
 DVM Dr. med. vet.
 DipECVDI

A soft tissue membrane is bulging ventrally into the lumen of the cervical tracheal segment. The trachea is normal in diameter and presents the anticipated course. The luminal outline of the trachea is smooth. The bronchial tree presents with thin walls and tapers uniformly towards the periphery as expected.

The lung parenchyma presents the expected architecture and opacity; the intrapulmonary vascular branching is seen up to the third order lung vessels.

HOSPITAL NAME

Blandford AH

The diaphragm is well delineated with even surface and the expected mild cranial bulging of the diaphragmatic cupola.

RADIOGRAPHIC DIAGNOSIS

- Obesity
- Left sided cardiomegaly without signs of decompensation
- Redundant tracheal membrane

REFERRING VET

Dr. Russ Lapierre

INTERPRETATION OF THE FINDINGS & FURTHER RECOMMENDATIONS
INVOICE

44550

The most likely underlying cause for the left sided cardiomegaly is mitral valve disease. At this point there is no sign of decompensation. A cardiac echo is considered beneficial for further assessment of cardiac chamber size and function.

The clinical relevance of the redundant tracheal membrane is questionable but can present a precursor for tracheal collapse.

DATE

8/9/23

Weight management is considered beneficial as obesity is a known predisposing factor for cough and impaired pulmonary function.



PATIENT

Hope Costa

TECHNICAL COMMENTS

Human fingers are seen in the primary beam, please consider radiation safety guidelines!

SPECIES

Canine

BREED

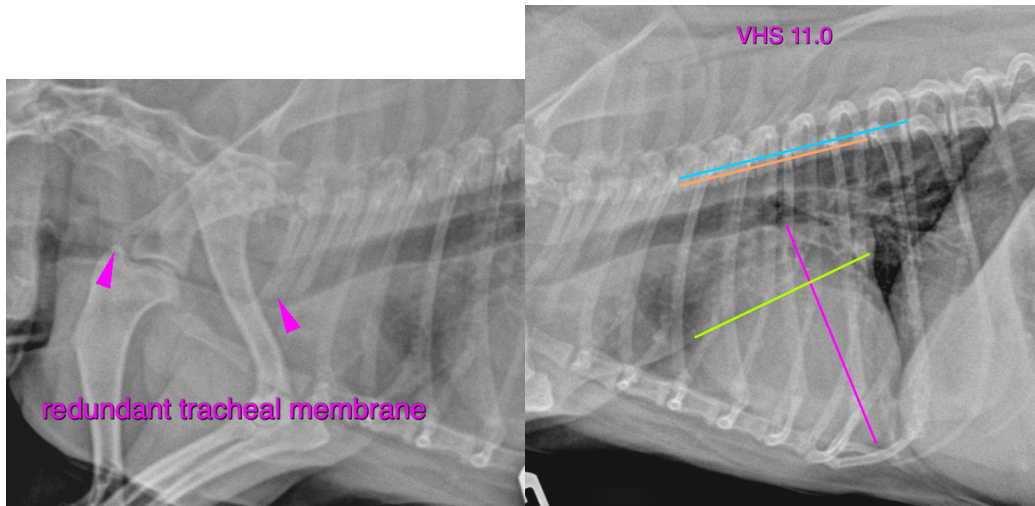
Maltese

SEX

Female

AGE

13



INTERPRETED BY

Sebastian Schaub,
DVM Dr. med. vet.
DipECVDI

The information and recommendations provided are based on the images presented by the referring veterinarian. No evaluation can be communicated regarding pathology that was not visible in the image/video clips provided.

Thank you for this referral. If the clinical or image interpretation does not parallel your findings or if I can be of any further assistance please contact me.

HOSPITAL NAME

Blandford AH

Sebastian Schaub, Sebastian Schaub, DVM, Dr. med. vet. DipECVDI
sebast.schaub@gmail.com

REFERRING VET

Dr. Russ Lapierre

INVOICE

44550

DATE

8/9/23