



**PATIENT**

Electra Ballantyne

**PRESENTING CLINICAL SIGNS**

cough on and off for several months

**RADIOGRAPHIC STUDY OF THE THORAX**

Radiographs of the thorax in three imaging planes are provided for review.

**SPECIES**

Feline

**RADIOGRAPHIC FINDINGS**

The surrounding bony structures are within normal limits.

**BREED**

Sphinx

The extrathoracic soft tissues present homogeneous without abnormalities.

The cardiac silhouette is moderately enlarged and elongated, occupying approximately 80% of the thoracic height. In the VD view, the cardiac silhouette has a valentine shape and is occupying 75% of the thoracic width. The pulmonary vasculature is within normal limits.

**SEX**

Female

The cranial mediastinum presents the expected soft tissue opacity. The mediastinal width is less than twice the width of the vertebral column at the same level.

The trachea is normal in diameter and presents the anticipated course. The luminal outline of the trachea is smooth.

**AGE**

6 Years

Generalized mild to moderate peribronchial cuffing is appreciated.

The lung parenchyma presents the expected architecture and opacity; the intrapulmonary vascular branching is seen up to the third order lung vessels.

The diaphragm is well delineated with even surface and the expected mild cranial bulging of the diaphragmatic cupola.

**INTERPRETED BY**

Sebastian Schaub, DVM  
Dr. med. vet. DipECVDI

**RADIOGRAPHIC DIAGNOSIS**

- Generalized significant cardiomegaly
- Bronchial lung pattern

**HOSPITAL NAME**

Chappelle Veterinary  
Clinic

**INTERPRETATION OF THE FINDINGS & FURTHER RECOMMENDATIONS**

The main finding is the generalized cardiomegaly and underlying cardiomyopathy is very likely – such as hypertrophic cardiomyopathy (HCM). At this point there is no evidence of decompensation. A cardiac echo is strongly recommended.

The bronchial lung pattern in combination with the history of cough is suggestive for feline bronchial disease ± bacterial or viral superinfection.

**REFERRING VET**

Bassam Abdelmelak

**INVOICE**

53366

**DATE**

8-9-22



**PATIENT**

Electra Ballantyne

**SPECIES**

Feline

**BREED**

Sphinx

**SEX**

Female

**AGE**

6 Years

**INTERPRETED BY**

Sebastian Schaub, DVM  
Dr. med. vet. DipECVDI

**HOSPITAL NAME**

Chappelle Veterinary  
Clinic

**REFERRING VET**

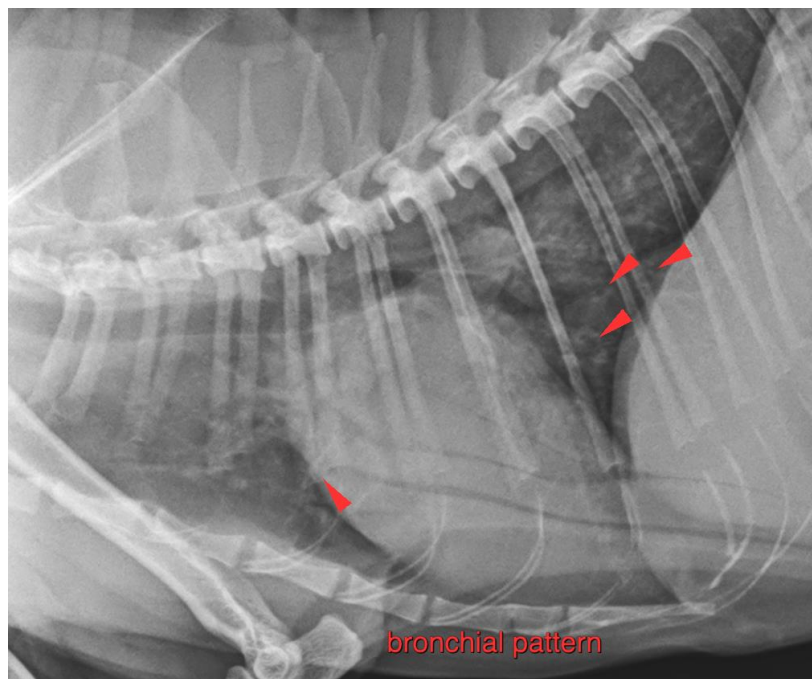
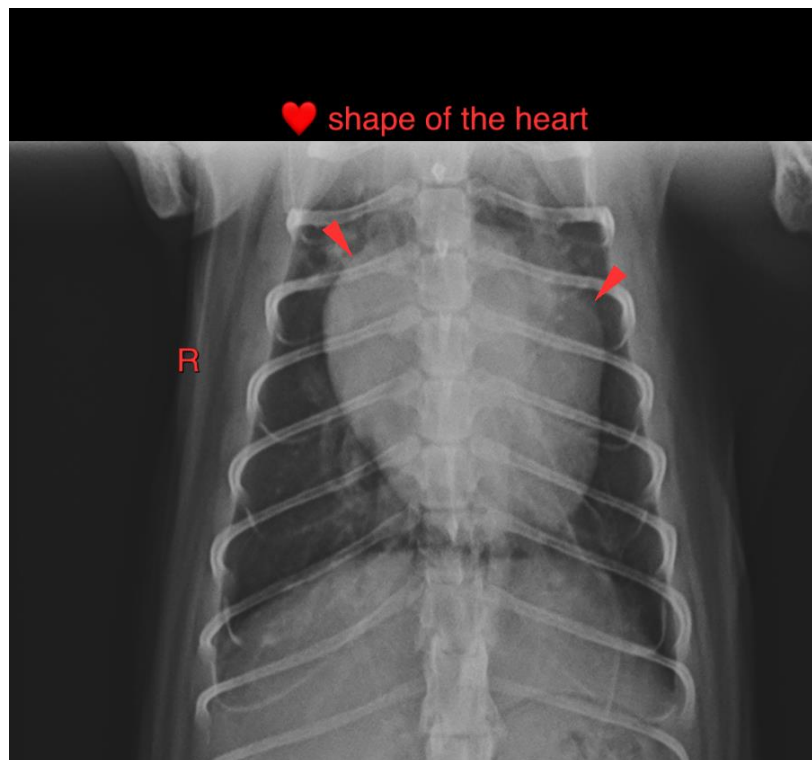
Bassam Abdelmelak

**INVOICE**

53366

**DATE**

8-9-22





**PATIENT**

Electra Ballantyne

The information and recommendations provided are based on the images presented by the referring veterinarian/sonographer. No evaluation can be communicated regarding pathology that was not visible in the image/video clips provided.

**SPECIES**

Feline

Thank you for this referral. If the clinical or image interpretation does not parallel your findings or if I can be of any further assistance please contact me.

**BREED**

Sphinx

**Sebastian Schaub**, Sebastian Schaub, DVM, Dr. med. vet. DipECVDI  
sebast.schaub@gmail.com

**SEX**

Female

**AGE**

6 Years

**INTERPRETED BY**

Sebastian Schaub, DVM  
Dr. med. vet. DipECVDI

**HOSPITAL NAME**

Chappelle Veterinary  
Clinic

**REFERRING VET**

Bassam Abdelmelak

**INVOICE**

53366

**DATE**

8-9-22