



**PATIENT PRESENTING CLINICAL SIGNS**

**Kitty Duarte** History: Initially presented for hyporexia. Draining abscess along R mandible treated with Convenia 7/28. Appetite improved, recent onset anorexia and occasional vomiting.

**SPECIES** Abnormal PE/Chem/CBC/UA Results: Trying to bite when intra-oral exam attempted. Mild swelling along R mandible, no draining tract/discharge. Dental radiographs revealed multiple resorptive lesions and crown fracture 103, root fracture 303, planning extractions in future.  
**Feline**

**COMPUTED TOMOGRAPHIC STUDY OF THE SKULL**

**BREED**

DMH

A high resolution pre- and post-contrast CT study of the skull is provided for review.

**COMPUTED TOMOGRAPHIC FINDINGS**

**SEX**

Spayed Female

The tooth elements 301, 307, 404 and 407 are absent. The tooth elements 107 & 207 show resorptive lesions in the junction between the crown and root. Ankylosis of the tooth roots of triadan 104 & 204 is seen with resorption of the roots. Nearly complete resorption of the root of triadan 304 is noted. Triadan 309 presents lytic lesions of the crown.

**AGE**

11 Years

The nasal cavity presents the expected aerated spaces between thin and even conchae and turbinates with smooth mucosal lining. The roof of the nasopharynx is moderately swollen and presents a mild undulating surface.

**INTERPRETED BY**

Sebastian Schaub,  
DVM Dr. med. vet.  
DipECVDI

Both temporomandibular joints present congruent joint spaces with even subchondral bone surfaces and are considered within normal limits.

Both tympanic bullae are aerated, the mucosal lining is not seen, the bony wall is smooth and thin. The external ear canals are within normal limits.

**HOSPITAL NAME**

Healing Spirit AW

The brain presents no deviation from normal anatomy and symmetry. The brain parenchyma is homogeneous and within normal limits for attenuation and distribution of contrast enhancement. The ventricular system is non-dilated and symmetric.

**REFERRING VET**

Desen Ertunc

The submandibular and medial retropharyngeal lymph nodes are prominent, a normal short-to-long-axis-ratio is < 0.5, the attenuation and contrast enhancement pattern is uniform. A right lateral retropharyngeal lymph node is present and prominent.

A mild swelling of the subcutaneous tissue along the ventrolateral aspect of the right body of the mandible is seen.

**INVOICE**

12493

**COMPUTED TOMOGRAPHIC DIAGNOSIS**

- Multiple dental resorptive lesions, see above

**DATE**

8/9/21



**PATIENT**

Kitty Duarte

- Generalized lymphadenopathy of the lymph nodes of the skull and prominent nasopharyngeal tonsils
- Ankylosis tooth roots 104 & 204 with tooth root resorption
- Multiple absent teeth, see above

**SPECIES**

Feline

**INTERPRETATION OF THE FINDINGS & FURTHER RECOMMENDATIONS**

The findings fit the history of resorptive dental lesions of multiple teeth.

**BREED**

DMH

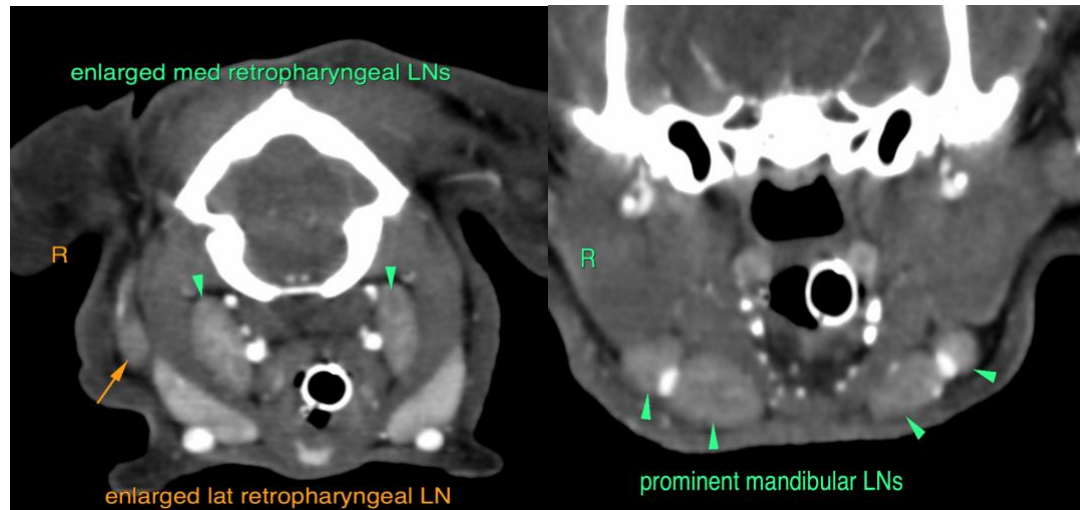
There is generalized enlargement of the lymph nodes of the skull and lymphoid tissue in the nasopharynx, recommend FNA sampling to confirm diagnosis of reactive hyperplasia and rule out neoplastic infiltration such as round cell neoplasia.

**SEX**

Spayed Female

**AGE**

11 Years



**INTERPRETED BY**

Sebastian Schaub, DVM Dr. med. vet. DipECVDI

**The information and recommendations provided are based on the images presented by the referring veterinarian. No evaluation can be communicated regarding pathology that was not visible in the image/video clips provided.**

**HOSPITAL NAME**

Healing Spirit AW

Thank you for this referral. If the clinical or image interpretation does not parallel your findings or if I can be of any further assistance please contact me.

**REFERRING VET**

Desen Ertunc

**Sebastian Schaub**, Sebastian Schaub, DVM, Dr. med. vet. DipECVDI  
sebast.schaub@gmail.com

**INVOICE**

12493

**DATE**

8/9/21



**PATIENT**

Kitty Duarte

**SPECIES**

Feline

**BREED**

DMH

**SEX**

Spayed Female

**AGE**

11 Years

**INTERPRETED BY**

Sebastian Schaub,  
DVM Dr. med. vet.  
DipECVDI

**HOSPITAL NAME**

Healing Spirit AW

**REFERRING VET**

Desen Ertunc

**INVOICE**

12493

**DATE**

8/9/21