


PATIENT PRESENTING CLINICAL SIGNS

Rumble Kolvek
 subjective bony enlargement of ulnar process.. Largely nonweight bearing RF in exam room when standing. Guarded posture when palpating carpal area. _Grade 1 lameness when walking
 Abnormal PE/Chem/CBC/UA Results: subjective bony enlargement of ulnar process. Largely non weight bearing RF in exam room when standing. Guarded posture when palpating carpal area. Grade 1 lameness when walking _Today neg for 4Dx testing

SPECIES

Canine

RADIOGRAPHIC STUDY OF THE RIGHT CARPAL JOINT
BREED

Radiographs of the right carpal joint in two orthogonal imaging planes are provided for review.

GSH x
RADIOGRAPHIC FINDINGS

At the caudolateral aspect of the distal fourth of the diaphysis of the ulna, a small exostosis is appreciated.

SEX

Male

The osseous and soft tissue structures of the right carpal joint are within normal limits.

RADIOGRAPHIC DIAGNOSIS
AGE

4 Years

- Incidental small exostosis distal aspect of right ulna
- Normal right carpal joint

INTERPRETATION OF THE FINDINGS & FURTHER RECOMMENDATIONS
INTERPRETED BY

 Sebastian Schaub,
 DVM Dr. med. vet.
 DipECVDI

The radiographic study of the right carpal joint presents without clinically relevant abnormalities, there are no signs of aggressive bone lesions nor soft tissue swelling.

TECHNICAL COMMENTS

Human fingers are seen in the primary beam, please consider radiation safety guidelines!

HOSPITAL NAME

Blandford AH

REFERRING VET

Dr. Lapierre Russ

INVOICE

44561

DATE

8/8/23



PATIENT

Rumble Kolvek

SPECIES

Canine

BREED

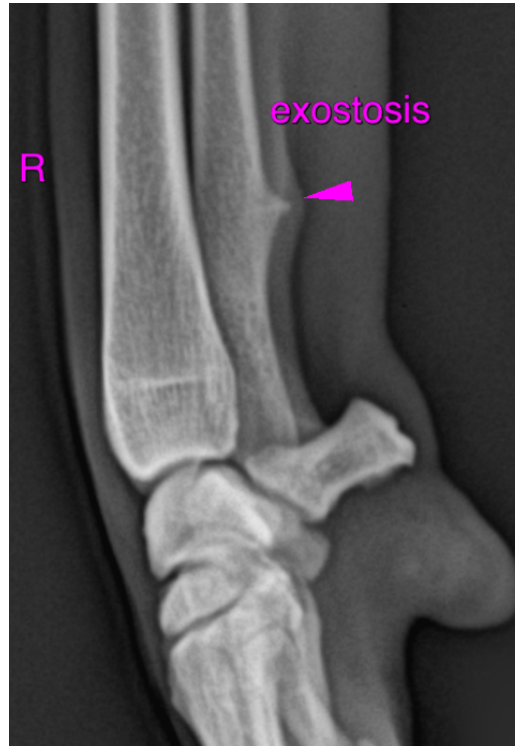
GSH x

SEX

Male

AGE

4 Years



INTERPRETED BY

Sebastian Schaub,
DVM Dr. med. vet.
DipECVDI

The information and recommendations provided are based on the images presented by the referring veterinarian. No evaluation can be communicated regarding pathology that was not visible in the image/video clips provided.

Thank you for this referral. If the clinical or image interpretation does not parallel your findings or if I can be of any further assistance please contact me.

HOSPITAL NAME

Blandford AH

Sebastian Schaub, Sebastian Schaub, DVM, Dr. med. vet. DipECVDI
sebast.schaub@gmail.com

REFERRING VET

Dr. Lapierre Russ

INVOICE

44561

DATE

8/8/23