



PATIENT PRESENTING CLINICAL SIGNS

PATIENT
Toast Alive
History of being febrile/inappetent for ~3 days Hospitalized on IV fluids for the weekend, normal temperature today (8/8/22)
Abnormal PE/Chem/CBC/UA Results: Suspect rods/cocci noted on urinalysis, Snap Heartworm/Tick test negative

SPECIES

Canine

COMPUTED TOMOGRAPHY OF THE THORAX AND ABDOMEN

A high resolution pre- and post-contrast CT study of the abdomen and a plain CT study of the thorax are provided for review.

BREED

Mixed

COMPUTED TOMOGRAPHIC FINDINGS

Thorax

The bony and surrounding soft tissue structures are within normal limits.

SEX

Male Neutered

Level with the middle tracheobronchial lymph node, centered on the carina of the trachea, a uniform soft tissue attenuating, ill-defined mass is appreciated. The hilar mass is distorting the principal bronchi at the same level.

AGE

2 Years

The cardiovascular structures including the pulmonary vasculature are within normal limits.

The lung lobes present a disseminated pattern with interstitial pinpoint nodules throughout the lung parenchyma.

INTERPRETED BY

Sebastian Schaub, DVM
Dr. med. vet. DipECVDI

Small incidental gas pockets are seen within the esophageal lumen, there is no evidence of abnormal dilation.

Abdomen

The serosal fat presents normal attenuation behavior. There is no evidence of peritoneal effusion or peritonitis.

HOSPITAL NAME

Catskill Veterinary Services, PLLC

Both kidneys present within normal limits for size, shape and organ architecture. After contrast administration a bilaterally symmetric and uniform nephro- and pyelogram is noted.

The adrenal glands are within normal limits for size, shape and organ architecture.

REFERRING VET

Dr. Joseph D'Abbraccio

Both liver and spleen present with normal shape, even surface, uniformly attenuating parenchyma and homogeneous contrast enhancement, unremarkable.

The portal vein presents a normal order of its tributary veins and intrahepatic branching. No abnormal vessel is noted inside and outside of the liver parenchyma.

INVOICE

53343

The pancreas is evenly contoured, the pancreatic parenchyma is homogeneous and presents uniform contrast enhancement.

The position, delineation, wall and content of the gastrointestinal tract are considered within normal limits throughout.

DATE

8-8-22

The periarticular bones of both coxofemoral joints present mild to moderate osteophyte new bone formation.

The right testicle is located in the subcutaneous tissue in the right inguinal region. The left testicle is seen in the left caudal abdomen, as an irregular soft tissue attenuating structure with a mild



PATIENT heterogeneous contrast enhancement pattern – most accentuated level with the plexus pampiniformis.

Toast Alive

COMPUTED TOMOGRAPHIC DIAGNOSIS

SPECIES

Canine

- Soft tissue mass region of middle tracheobronchial lymph node with compression of the principal bronchi
- Disseminated micronodular interstitial lung pattern
- Bilateral cryptorchism, right inguinal, left abdominal

BREED

Mixed

INTERPRETATION OF THE FINDINGS & FURTHER RECOMMENDATIONS

SEX

Male Neutered

The CT findings are highly suggestive for significant enlargement of the middle tracheobronchial lymph node and micronodular pattern of the lung parenchyma – the findings are suggestive either for fungal pneumonia and granulomatous lymphadenopathy (e.g. Histoplasmosis, Coccidiomycosis) or neoplastic disease (e.g. pulmonary lymphoma, carcinoma). As minimally invasive FNA sampling of the enlarged lymph node is not feasible, bronchoscopy including BAL is recommended as advanced diagnostic tool as well as testing for potential mycotic infectious agents. Theoretically Mycobacterium infection is a potential as well, but the odds are low.

AGE

2 Years

INTERPRETED BY

Sebastian Schaub, DVM
Dr. med. vet. DipECVDI

HOSPITAL NAME

Catskill Veterinary
Services, PLLC

REFERRING VET

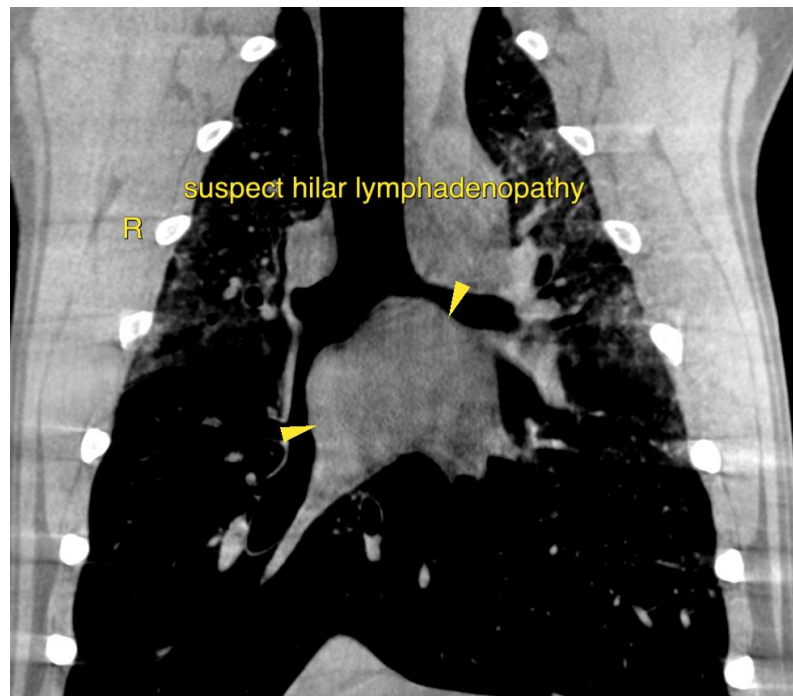
Dr. Joseph
D'Abbraccio

INVOICE

53343

DATE

8-8-22





PATIENT

Toast Alive

SPECIES

Canine

BREED

Mixed

SEX

Male Neutered

AGE

2 Years

INTERPRETED BY

Sebastian Schaub, DVM
Dr. med. vet. DipECVDI

HOSPITAL NAME

Catskill Veterinary
Services, PLLC

REFERRING VET

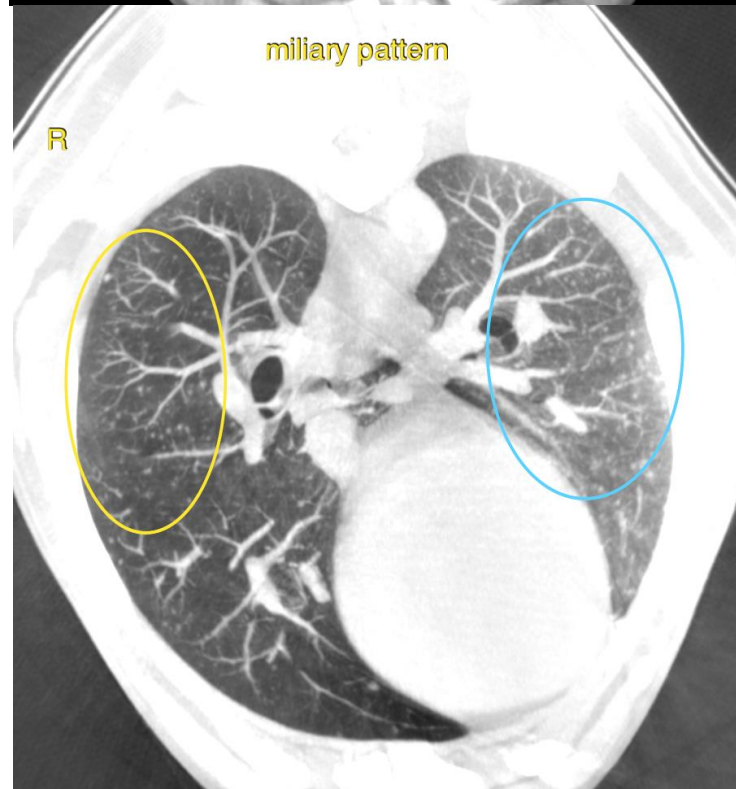
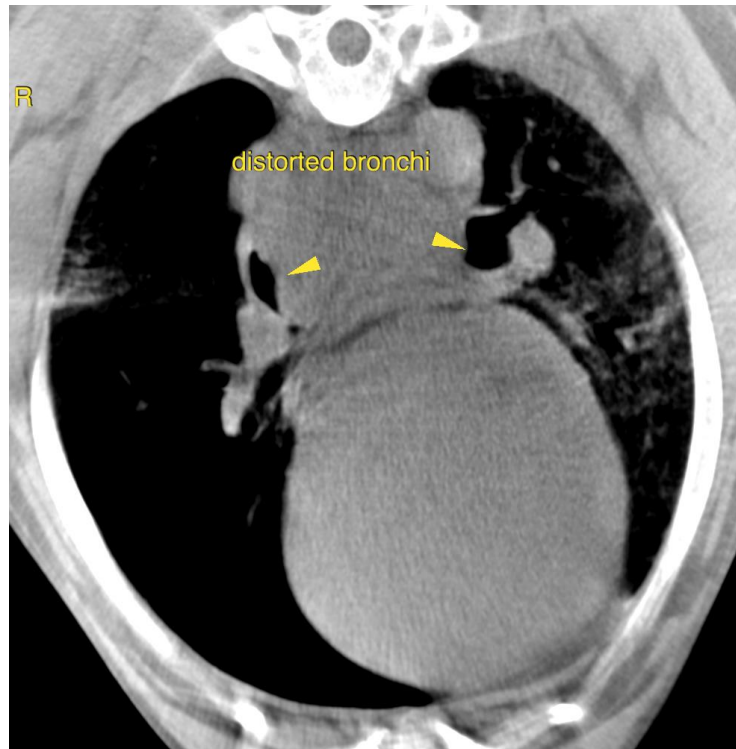
Dr. Joseph
D'Abbraccio

INVOICE

53343

DATE

8-8-22





PATIENT

Toast Alive

The information and recommendations provided are based on the images presented by the referring veterinarian/sonographer. No evaluation can be communicated regarding pathology that was not visible in the image/video clips provided.

SPECIES

Canine

Thank you for this referral. If the clinical or image interpretation does not parallel your findings or if I can be of any further assistance please contact me.

BREED

Mixed

Sebastian Schaub, Sebastian Schaub, DVM, Dr. med. vet. DipECVDI
sebast.schaub@gmail.com

SEX

Male Neutered

AGE

2 Years

INTERPRETED BY

Sebastian Schaub, DVM
Dr. med. vet. DipECVDI

HOSPITAL NAME

Catskill Veterinary
Services, PLLC

REFERRING VET

Dr. Joseph
D'Abbraccio

INVOICE

53343

DATE

8-8-22