



PATIENT

Louie Fox

PRESENTING CLINICAL SIGNS

Reason for Visit: swollen front right leg. History: 6-7yr old SF shorthair is presented today b/c P is a neighborhood kitty some years ago actually owners moved & left her behind the neighborhood has been taking good care of her but who brought P in is the main caretaker & states that Lulu hasn't been walking up the steps to her food & water so O started taking the food downstairs to her but thats when O noticed that P's front right leg was swollen O also has noticed a cut on one of the back legs. There is another neighborhood cat that the other people have seen go into lulu's territory & they have fought before P has come home with scratches. O unsure is P is in pain when she touched the arm P pulled away but did not cry out in anyway.

SPECIES

Feline

BREED

DSH

SEX

NM

AGE

9 Years

Abnormal PE/Chem/CBC/UA Results: Physical Examination Key -- (N= Normal, A= Abnormal) CV/Respiratory: Normal heart rate and rhythm, grade II/VI heart murmur, pulses strong and synchronous, normal bronchovesicular sounds. EENT: Clear OU (Florida spots OS). AU" mild black cerumen, no erythema or swelling present. No nasal discharge. No cough on tracheal palpation. Oral cavity: Moderate dental tartar Musculoskeletal: BCS = 5/9. Ambulatory x 4. RF: grade 3/5 lameness, firm soft tissue swelling on antebrachium (from elbow to carpus), healed scab at dorsal aspect of proximal antebrachium. Uro/Perineum: Neutered male Abd/GI: Soft, non-painful. No masses or fluid wave palpated Lymph Nodes: No peripheral lymphadenopathy Neurological: Alert and appropriate. No significant abnormalities Skin: Good hair coat. No ectoparasites seen Mentation: BAR Hydration: N Fecal: Not performed today

RADIOGRAPHIC STUDY OF THE RIGHT ELBOW JOINT

Radiographs of the right elbow joint in two orthogonal imaging planes are provided for review.

INTERPRETED BY

Sebastian Schaub, DVM
Dr. med. vet. DipECVDI

RADIOGRAPHIC FINDINGS

In the craniocaudal view of the included left elbow joint, no abnormalities of the osseous and surrounding soft tissue structures are appreciated.

HOSPITAL NAME

DPC Veterinary
Hospital

The right elbow joint presents smooth osseous margins. At the medial aspect of the medial coronoid process of the right elbow joint, two well-defined, roundish mineral opaque bodies are appreciated, measuring up to 2.5 mm in size. At the caudal and medial aspect, the right antebrachium presents a moderate homogeneous soft tissue swelling, extending from the level of the elbow joint distally up to the distal third of the right antebrachium.

The right radius & ulnar present without abnormalities.

REFERRING VET

Dr. Rivera

RADIOGRAPHIC DIAGNOSIS

- Soft tissue swelling mediocaudal aspect right antebrachium
- Mineralized bodies medial aspect right elbow joint

INVOICE

53352

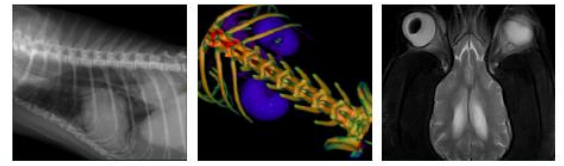
INTERPRETATION OF THE FINDINGS & FURTHER RECOMMENDATIONS

The main finding is the soft tissue swelling of the right antebrachium and inflammatory (e.g. abscess, empyema), traumatic (e.g. hematoma) or less likely neoplastic origin are considered likely. Ultrasound can be used to screen for fluid pockets, possibly warranting drainage.

DATE

8-8-22

The mineralized bodies are likely unrelated to the soft tissue swelling and are suggestive for synovial osteochondromatosis.



PATIENT

Louie Fox

SPECIES

Feline

BREED

DSH

SEX

NM

AGE

9 Years

INTERPRETED BY

Sebastian Schaub, DVM
Dr. med. vet. DipECVDI

HOSPITAL NAME

DPC Veterinary
Hospital

REFERRING VET

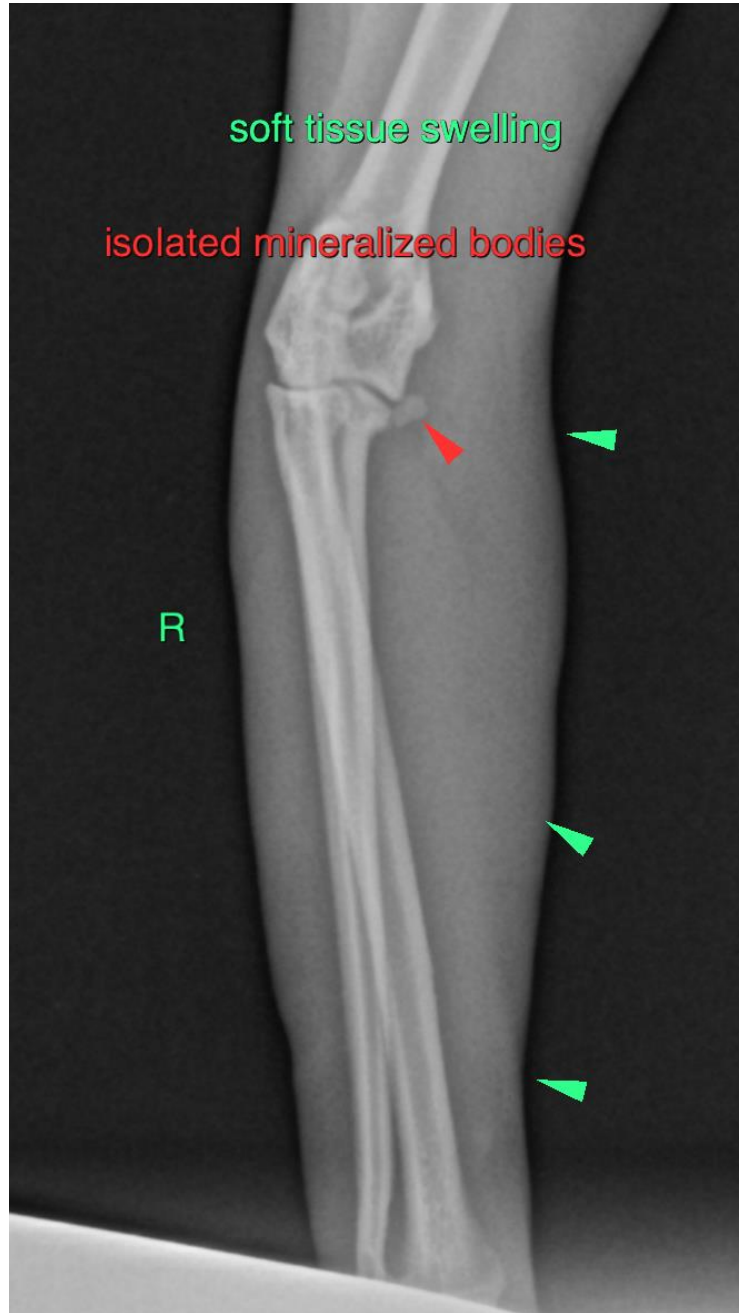
Dr. Rivera

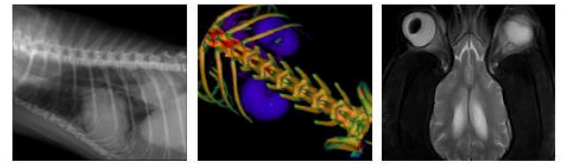
INVOICE

53352

DATE

8-8-22





PATIENT

Louie Fox

The information and recommendations provided are based on the images presented by the referring veterinarian/sonographer. No evaluation can be communicated regarding pathology that was not visible in the image/video clips provided.

SPECIES

Feline

Thank you for this referral. If the clinical or image interpretation does not parallel your findings or if I can be of any further assistance please contact me.

Sebastian Schaub, Sebastian Schaub, DVM, Dr. med. vet. DipECVDI
sebast.schaub@gmail.com

BREED

DSH

SEX

NM

AGE

9 Years

INTERPRETED BY

Sebastian Schaub, DVM
Dr. med. vet. DipECVDI

HOSPITAL NAME

DPC Veterinary
Hospital

REFERRING VET

Dr. Rivera

INVOICE

53352

DATE

8-8-22