


PATIENT PRESENTING CLINICAL SIGNS

Gunnarr Potthoff Last couple of days he has been having some wet shallow breathing. Seems like his eyes are runny as well. Seems to retching/ cough as well but nothing comes up. Dint want to eat his breakfast this morning.

SPECIES

Canine

Abnormal PE/Chem/CBC/UA Results: PE: was normal uncomfortable to palpation and INFECTION RIGHT EAR. NO RECENT BLOODWORK DONE

RADIOGRAPHIC STUDY OF THE THORAX
BREED

Weimaraner

Radiographs of the thorax in three imaging planes are provided for review.

RADIOGRAPHIC FINDINGS
SEX

Neutered Male

The surrounding bony structures are within normal limits.

The extrathoracic soft tissues present homogeneous without abnormalities.

The heart is of normal size and shape, there is no evidence of cardiac chamber or vascular enlargement. The pulmonary vasculature is within normal limits.

AGE

11 Years 9 Months

The cranial mediastinum presents the expected soft tissue opacity. The mediastinal width is less than twice the width of the vertebral column at the same level.

INTERPRETED BY

Sebastian Schaub,
 DVM Dr. med. vet.
 DipECVDI

The trachea is normal in diameter and presents the anticipated course. The luminal outline of the trachea is smooth.

The bronchial tree presents with thin walls and tapers uniformly towards the periphery as expected. The caudal part of the left caudal lung lobe is consolidated with air-bronchograms. The volume of the left cranial lung lobe is maintained.

HOSPITAL NAME

Elizabeth AH

The diaphragm is well delineated with even surface and the expected mild cranial bulging of the diaphragmatic cupola.

RADIOGRAPHIC DIAGNOSIS
REFERRING VET

Dr. Kim Allyn

- Alveolar lung pattern caudal part left cranial lung lobe

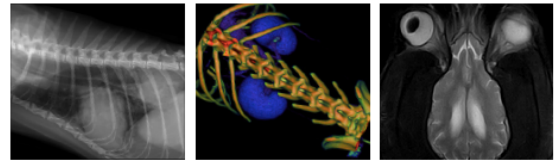
INTERPRETATION OF THE FINDINGS & FURTHER RECOMMENDATIONS
INVOICE

44539

The ventrally distributed alveolar pattern of the left cranial lung lobe is highly suggestive for pneumonia - bacterial origin is likely. Potentials can include pulmonary hemorrhage or neoplastic infiltration of the caudal part of the left cranial lung. Recommend complementing workup by lab work to screen for inflammatory changes.

DATE

8/7/23



PATIENT

Gunnarr Potthoff

SPECIES

Canine

BREED

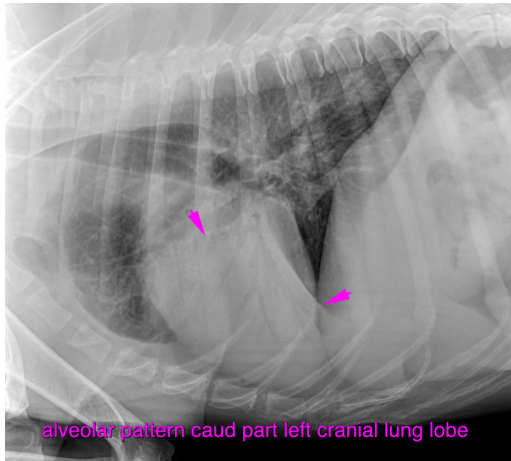
Weimaraner

SEX

Neutered Male

AGE

11 Years 9 Months



The information and recommendations provided are based on the images presented by the referring veterinarian. No evaluation can be communicated regarding pathology that was not visible in the image/video clips provided.

Thank you for this referral. If the clinical or image interpretation does not parallel your findings or if I can be of any further assistance please contact me.

Sebastian Schaub, Sebastian Schaub, DVM, Dr. med. vet. DipECVDI
sebast.schaub@gmail.com

INTERPRETED BY

Sebastian Schaub,
DVM Dr. med. vet.
DipECVDI

HOSPITAL NAME

Elizabeth AH

REFERRING VET

Dr. Kim Allyn

INVOICE

44539

DATE

8/7/23