
**PATIENT PRESENTING CLINICAL SIGNS**

Baxter Choudhry Acute vomiting and colitis  
 Abnormal PE/Chem/CBC/UA Results: CBC/chem: NSF Fecal scan: NPS

**SPECIES RADIOGRAPHIC STUDY OF THE ABDOMEN**

Canine Radiographs of the abdomen in two orthogonal imaging planes are provided for review.

**RADIOGRAPHIC FINDINGS**
**BREED**

The surrounding bony structures are within normal limits.

**Breed**

Samoyed No abnormalities of the extraabdominal soft tissues are noted. The abdominal wall is smooth and thin.

**SEX**

The serosal detail is maintained throughout the peritoneal and retroperitoneal space.

**Sex**

Neutered Male The liver is appropriate in position, size and presents uniform opacity.

**AGE**

The splenic head is in the anticipated position and within normal limits for size and opacity. The splenic body and tail are considered normal for position, size, shape and opacity.

**Age**

2 Years Both kidneys are seen and present with normal size, shape, delineation and opacity. The urinary bladder is in its anticipated position. No radiopaque calculi are noted throughout the upper and lower urinary tract.

**INTERPRETED BY**

Sebastian Schaub,  
 DVM Dr. med. vet.  
 DipECVDI

The stomach is in its anticipated position. In the pyloric antrum of the stomach, at least two tubular, mineral opaque bodies is visible, measuring approximately 1.1 cm in height and up to 4.3 cm in length.

The small intestinal loops are of even diameter and non-dilated, a small amount of gas is seen within the small intestinal loops and considered within normal limits.

**HOSPITAL NAME**

Sunset AH

The colon is seen in the expected position, mildly distended by gas and otherwise empty.

**RADIOGRAPHIC DIAGNOSIS**

- Two mineral opaque gastric foreign bodies
- Mild gas distended small intestinal loops
- Empty, mild corrugated colon

**REFERRING VET**

Dr. Mayra Sanchez

**INTERPRETATION OF THE FINDINGS & FURTHER RECOMMENDATIONS**
**INVOICE**

44517

The mineral opaque bodies in the stomach can present ingested osseous material – correlate with the fed diet. There is no evidence of abnormal gas pattern or signs for gastrointestinal mechanical obstruction. The appreciated pattern of the small intestinal loops and the colon are supporting the presumptive diagnosis of gastroenteritis. If clinical signs are refractory to therapy, recommend follow up radiographs or a complete abdominal ultrasound examination.

**DATE**

8/7/23



**PATIENT**

Baxter Choudhry

**SPECIES**

Canine

**BREED**

Samoyed

**SEX**

Neutered Male

**AGE**

2 Years

**INTERPRETED BY**

Sebastian Schaub,  
DVM Dr. med. vet.  
DipECVDI

**HOSPITAL NAME**

Sunset AH

**REFERRING VET**

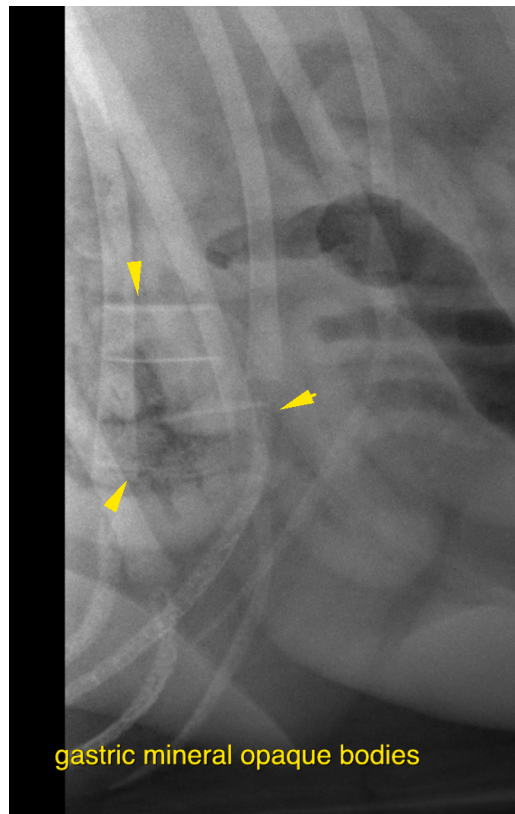
Dr. Mayra Sanchez

**INVOICE**

44517

**DATE**

8/7/23



**The information and recommendations provided are based on the images presented by the referring veterinarian. No evaluation can be communicated regarding pathology that was not visible in the image/video clips provided.**

Thank you for this referral. If the clinical or image interpretation does not parallel your findings or if I can be of any further assistance please contact me.

**Sebastian Schaub**, Sebastian Schaub, DVM, Dr. med. vet. DipECVDI  
sebast.schaub@gmail.com