



PATIENT

Niko Norrie

PRESENTING CLINICAL SIGNS

NON WEIGHT BEARING ON RIGHT HIND , SWALLEN RIGHT TARSAL TARSAL AREA
 MANIPULATION REVEALED A Crepitation SOUND
 Abnormal PE/Chem/CBC/UA Results: NORMAL

SPECIES

Feline

RADIOGRAPHIC STUDY OF THE TARSAL JOINTS

Radiographs of the tarsal joint in two imaging planes are provided for review.

RADIOGRAPHIC FINDINGS

BREED

DSH

The dorsoplantar view of the tarsal joints is moderately rotated.

The growth plates are age related open.

The right popliteal lymph node is prominent.

SEX

Male

The distal segment of the right crus and the right tarsal joint and metatarsal region present with a circumferential subcutaneous, homogeneous soft tissue swelling. The osseous structures of the left tarsal joint present without abnormalities. There is moderate inherent rotation of the dorsoplantar views, limiting the diagnostic value.

AGE

14 Weeks

RADIOGRAPHIC DIAGNOSIS

- Moderate circumferential soft tissue swelling right tarsal joint/distal aspect of the crus
- Lymphadenopathy right popliteal lymph node

INTERPRETED BY

Sebastian Schaub, DVM
 Dr. med. vet. DipECVDI

INTERPRETATION OF THE FINDINGS & FURTHER RECOMMENDATIONS

The main finding is the soft tissue swelling in the region of the right tarsal joint and traumatic or inflammatory origin are considered most likely. No abnormalities of the osseous structures are appreciated. If there is clinical evidence of joint effusion of the right talocrural joint, a synovial tap would be beneficial to rule in/out arthritis. In case of strong suspicion for instability of the tarsal joint or non-displaced epiphysiolysis, recommend stressed radiographs of the right tarsal joint under general anesthesia.

Suspect reactive hyperplasia of the right popliteal lymph node.

HOSPITAL NAME

St. Catherine's Animal
 Hospital

REFERRING VET

Dr. Boctor

INVOICE

53307

DATE

8-6-22



PATIENT

Niko Norrie

SPECIES

Feline

BREED

DSH

SEX

Male

AGE

14 Weeks

INTERPRETED BY

Sebastian Schaub, DVM
Dr. med. vet. DipECVDI

HOSPITAL NAME

St. Catherine's Animal
Hospital

REFERRING VET

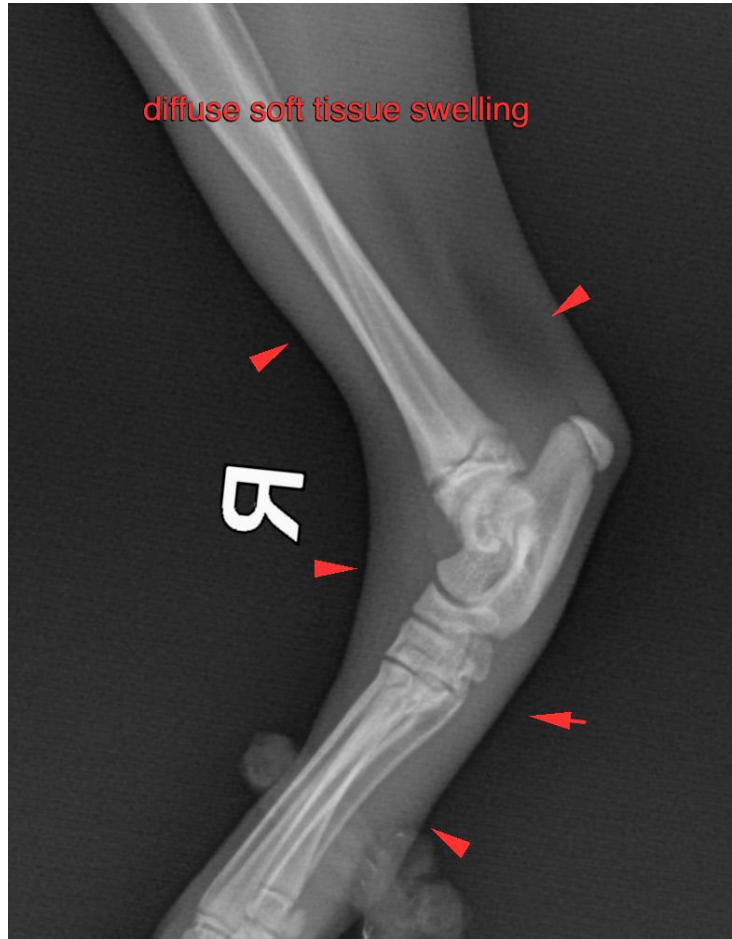Dr. Boctor

INVOICE

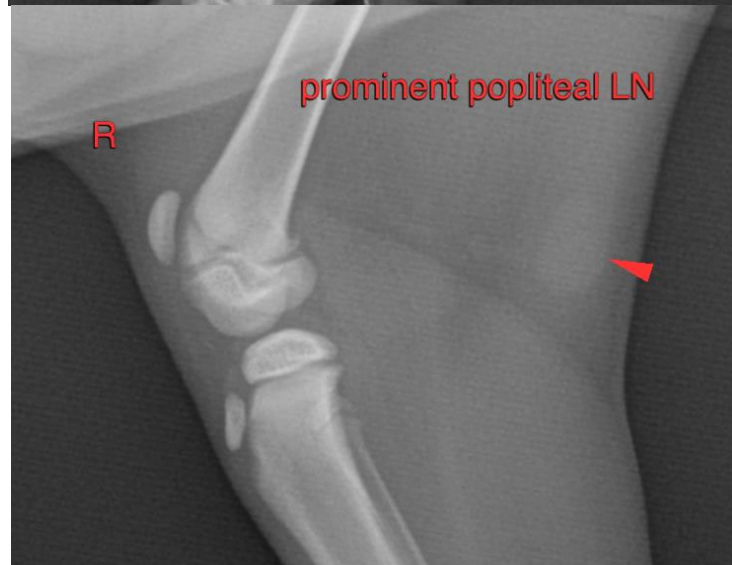
53307

DATE

8-6-22



diffuse soft tissue swelling



prominent popliteal LN



PATIENT

Niko Norrie

SPECIES

Feline

The information and recommendations provided are based on the images presented by the referring veterinarian/sonographer. No evaluation can be communicated regarding pathology that was not visible in the image/video clips provided.

BREED

DSH

Thank you for this referral. If the clinical or image interpretation does not parallel your findings or if I can be of any further assistance please contact me.

Sebastian Schaub, Sebastian Schaub, DVM, Dr. med. vet. DipECVDI
sebast.schaub@gmail.com

SEX

Male

AGE

14 Weeks

INTERPRETED BY

Sebastian Schaub, DVM
Dr. med. vet. DipECVDI

HOSPITAL NAME

St. Catherine's Animal
Hospital

REFERRING VET

Dr. Boctor

INVOICE

53307

DATE

8-6-22