



PATIENT PRESENTING CLINICAL SIGNS

Hana Hashemi PATIENT HAS BEEN ON AND OFF LIMPING PROMINENTLY ON LEFT FORELIMB BUT ALTERNATES TO RIGHT FORELIMB, SYMPTOMS HAVE BEEN GOING ON FOR COUPLE OF WEEKS WITH EPISODE OF LIMPING FOR FEW DAY STRAIGHT. O NOTED JUMPING PROVOKES PAIN RESPONSE, AND LEFT FORELIMB LOOKS INFLAMED COMPARED TO RIGHT

SPECIES

Canine **RADIOGRAPHIC STUDY OF THE ELBOW AND CARPAL JOINTS**

Radiographs of the elbow and carpal joints bilaterally are provided for review.

BREED

Goldendoodle

RADIOGRAPHIC FINDINGS

Both elbow joints present smooth osseous margins of the periarticular bones. The contour of the medial coronoid process of the elbow joints cannot be clearly defined. The surrounding soft tissue structures of the elbow joints are unremarkable.

SEX

Spayed Female

The osseous and surrounding soft tissue structures of the carpal joints are within normal limits. The irregularity and heterogeneity of the distal metaphysis of the radius and ulna bilaterally is considered as a normal finding, due to active osseous remodeling due to growth.

AGE

5 Months

RADIOGRAPHIC DIAGNOSIS

- Normal elbow joints
- Normal carpal joints

INTERPRETED BY

Sebastian Schaub,
DVM Dr. med. vet.
DipECVDI

INTERPRETATION OF THE FINDINGS & FURTHER RECOMMENDATIONS

The radiographic study of the front limbs presents without abnormalities, explaining the history of alternative front limb lameness. The ill-defined contour of the medial coronoid process of the elbow joints can be a sequela to incomplete ossification due to the young age.

HOSPITAL NAME

Green Dog Dental
and Wellness

The information and recommendations provided are based on the images presented by the referring veterinarian/sonographer. No evaluation can be communicated regarding pathology that was not visible in the image/video clips provided.

REFERRING VET

Dr. Claudia Lau

Thank you for this referral. If the clinical or image interpretation does not parallel your findings or if I can be of any further assistance please contact me.

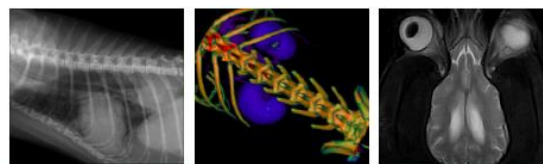
INVOICE

23808

Sebastian Schaub, Sebastian Schaub, DVM, Dr. med. vet. DipECVDI
info@sonopath.com

DATE

8/4/23



PATIENT

Hana Hashemi

SPECIES

Canine

BREED

Goldendoodle

SEX

Spayed Female

AGE

5 Months

INTERPRETED BY

Sebastian Schaub,
DVM Dr. med. vet.
DipECVDI

HOSPITAL NAME

Green Dog Dental
and Wellness

REFERRING VET

Dr. Claudia Lau

INVOICE

23808

DATE

8/4/23