



PATIENT PRESENTING CLINICAL SIGNS

Elvis 2256JE History: Progressive unilateral L side nasal discharge since January 2023 Mucoïd hemorrhagic progressing to epistaxis recently RDVM with course of non-targeted antibiotics with no benefit reported No steroid use reported No fungal testing completed Goal of imaging today

SPECIES Abnormal PE/Chem/CBC/UA Results: Labs with no systemic changes reported Normal PT/PTT

Canine **COMPUTED TOMOGRAPHIC STUDY OF THE SKULL**

A high resolution pre- and post-contrast CT study of the skull is provided for review.

BREED **COMPUTED TOMOGRAPHIC FINDINGS**

Basset Hound The pictured parts of the dentition are complete and unremarkable in all jaw quadrants.

SEX The left nasal cavity is obliterated by a soft tissue attenuating mass with multifocal interspersed granular mineralization. Advanced destruction of the associated conchal & turbinate structures is appreciated. The nasal septum is mildly deviated to the right by the mass effect.

Neutered Male

AGE Both temporomandibular joints present congruent joint spaces with even subchondral bone surfaces and are considered within normal limits.

8 Years 2 Months

Both tympanic bullae are aerated, the mucosal lining is not seen, the bony wall is smooth and thin. The external ear canals are within normal limits.

INTERPRETED BY The brain presents no deviation from normal anatomy and symmetry. The brain parenchyma is homogeneous and within normal limits for attenuation and distribution of contrast enhancement. The ventricular system is non-dilated and symmetric.

Sebastian Schaub,
DVM Dr. med. vet.
DipECVDI

The submandibular and medial retropharyngeal lymph nodes are small and elongated with a normal short-to-long-axis-ratio is < 0.5, the attenuation and contrast enhancement pattern is uniform.

HOSPITAL NAME **COMPUTED TOMOGRAPHIC DIAGNOSIS**

Gentle Doctor AH

- Left nasal soft tissue mass with dystrophic mineralization.

REFERRING VET **INTERPRETATION OF THE FINDINGS & FURTHER RECOMMENDATIONS**

Pete Bashara, DVM

The left nasal mineralizing soft tissue mass is highly concerning for primary nasal neoplasia. Differentials include osteosarcoma, adenocarcinoma, squamous cell carcinoma, transitional cell carcinoma, lymphosarcoma, other. A potential can be nasal hamartoma or granuloma (e.g. mycotic). Rhinoscopy including biopsy can be used as advanced diagnostic tests. If neoplastic disease can be confirmed the Adam tumor stage is T1.

INVOICE

23791

Consider full tumor staging.

DATE

8/4/23



PATIENT

Elvis 2256JE

SPECIES

Canine

BREED

Basset Hound

SEX

Neutered Male

AGE

8 Years 2 Months

INTERPRETED BY

Sebastian Schaub,
DVM Dr. med. vet.
DipECVDI

HOSPITAL NAME

Gentle Doctor AH

REFERRING VET

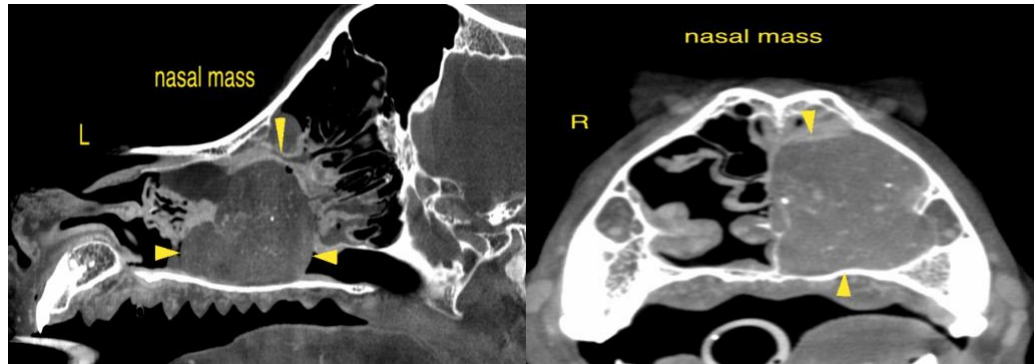
Pete Bashara, DVM

INVOICE

23791

DATE

8/4/23



The information and recommendations provided are based on the images presented by the referring veterinarian/sonographer. No evaluation can be communicated regarding pathology that was not visible in the image/video clips provided.

Thank you for this referral. If the clinical or image interpretation does not parallel your findings or if I can be of any further assistance please contact me.

Sebastian Schaub, Sebastian Schaub, DVM, Dr. med. vet. DipECVDI
info@sonopath.com