



PATIENT PRESENTING CLINICAL SIGNS

Cocoa Gaebel regurgitating blood, decreased eating and drinking.

RADIOGRAPHIC STUDY OF THE THORAX&ABDOMEN

SPECIES Radiographs of the thorax and abdomen are provided for review in two imaging planes

Canine **RADIOGRAPHIC FINDINGS**

Thorax

BREED The proximal segment of the humerus bilaterally and the glenoid cavity are misshaped and the proximal part of the humerus is displaced medial to the scapula

Toy Poodle

The extrathoracic soft tissues present homogeneous without abnormalities.

SEX The heart is of normal size and shape, there is no evidence of cardiac chamber or vascular enlargement. The pulmonary vasculature is within normal limits.

MN The cranial mediastinum presents the expected soft tissue opacity. The mediastinal width is less than twice the width of the vertebral column at the same level.

AGE Mild dorsoventral flattening of the caudal cervical segment of the trachea is seen.

12.5 Years The bronchial tree presents with thin walls and tapers uniformly towards the periphery as expected.

INTERPRETED BY The lung parenchyma presents the expected architecture and opacity; the intrapulmonary vascular branching is seen up to the third order lung vessels.

Sebastian Schaub, DVM
Dr. med. vet. DipECVDI

The diaphragm is well delineated with even surface and the expected mild cranial bulging of the diaphragmatic cupola.

HOSPITAL NAME Abdomen

Sunridge Vet Clinic The intervertebral disc space T12/T13 and T13/L1 are collapsed and the respective vertebral endplates present moderate spondylosis formation.

REFERRING VET No abnormalities of the extraabdominal soft tissues are noted. The abdominal wall is smooth and thin.

Dr. Magill The serosal detail is maintained throughout the peritoneal and retroperitoneal space.

INVOICE The hepatic volume is moderately increased the liver is protruding beyond the costal arch; the gastric axis is deviated caudally. The caudoventral hepatic margins are rounded.

53294 The splenic head is in the anticipated position and within normal limits for size and opacity. The splenic body and tail are considered normal for position, size, shape and opacity.

DATE Both kidneys are seen and present with normal size, shape, delineation and opacity. The urinary bladder is in its anticipated position. No radiopaque calculi are noted throughout the upper and lower urinary tract.

8-4-22 The stomach is in its anticipated position and presents normal content.



PATIENT

Cocoa Gaebel

The small intestinal loops are of even diameter and non-dilated, a small amount of gas is seen within the small intestinal loops and considered within normal limits.

The colon is seen in the expected position and presents with appropriate content.

SPECIES

Canine

RADIOGRAPHIC DIAGNOSIS

- Hepatomegaly
- Tracheal collapse
- Dysplasia of both shoulder joints with chronic medial & proximal luxation of the shoulder joints
- Chronic discopathy T12/T13 and T13/L1

BREED

Toy Poodle

INTERPRETATION OF THE FINDINGS & FURTHER RECOMMENDATIONS

The radiographic study presents no abnormality, explaining the presenting clinical signs. The stomach is moderately distended by chymus.

SEX

MN

Potentials for the hepatomegaly include metabolic hepatic disease/steroid induced hepatopathy, hepatitis or neoplastic infiltration. Ultrasound including FNA sampling can be used as minimally advanced diagnostic tests.

AGE

12.5 Years

INTERPRETED BY

Sebastian Schaub, DVM
Dr. med. vet. DipECVDI

HOSPITAL NAME

Sunridge Vet Clinic

REFERRING VET

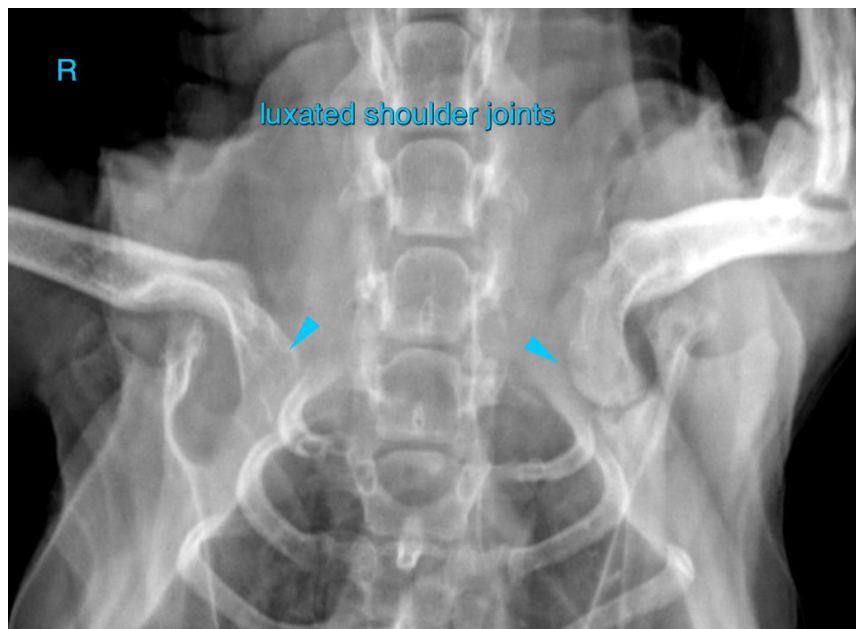
Dr. Magill

INVOICE

53294

DATE

8-4-22





PATIENT

Cocoa Gaebel

SPECIES

Canine

BREED

Toy Poodle

SEX

MN

AGE

12.5 Years

INTERPRETED BY

Sebastian Schaub, DVM
Dr. med. vet. DipECVDI

HOSPITAL NAME

Sunridge Vet Clinic

REFERRING VET

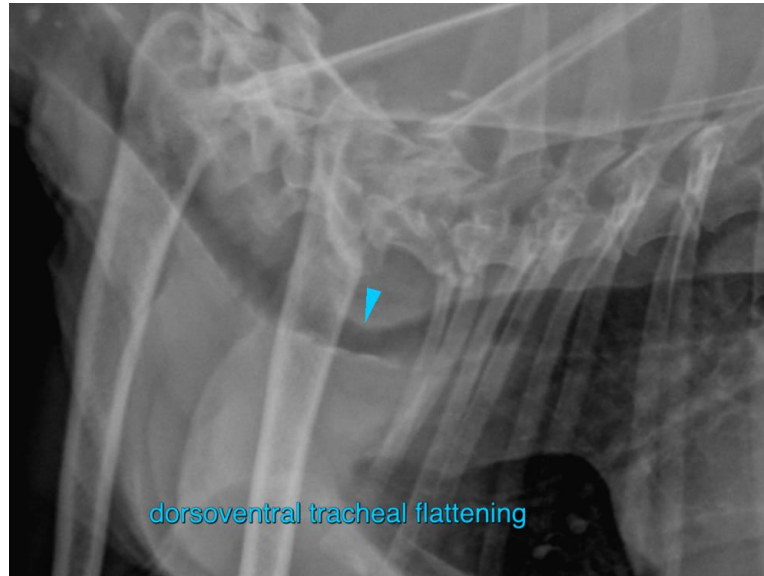Dr. Magill

INVOICE

53294

DATE

8-4-22



The information and recommendations provided are based on the images presented by the referring veterinarian/sonographer. No evaluation can be communicated regarding pathology that was not visible in the image/video clips provided.

Thank you for this referral. If the clinical or image interpretation does not parallel your findings or if I can be of any further assistance please contact me.

Sebastian Schaub, Sebastian Schaub, DVM, Dr. med. vet. DipECVDI
sebast.schaub@gmail.com