



PATIENT PRESENTING CLINICAL SIGNS

River Sanders River has a soft tissue sarcoma CT to review extent of mass. Mass debulked at RDVM on 1/03/22. Mass appeared in 2021 according to RDVM notes.
 Abnormal PE/Chem/CBC/UA Results: 8/31/22 CBC - RBC 4.47 M/uL Hematocrit 31.4 %
 Hemoglobin 11g/dL Lymphocytes 0.82 Chem - ALP 522 U/L

SPECIES

Canine

COMPUTED TOMOGRAPHY OF THE SKULL, THORAX AND ABDOMEN

A high resolution pre- and post-contrast CT study of the skull and abdomen and a post-contrast CT study of the thorax are provided for review.

BREED

COMPUTED TOMOGRAPHIC FINDINGS

Schnauzer/Miniature

Skull

Triadan 102, 110, 310, 311, 410 and 411 are absent. Triadan 201-203, 209 present a moderate widening of the periodontal space. The periodontal space of triadan 309 is periapical significantly widened, presenting a draining tract through the lateral cortex of the mandible

SEX

Spayed Female

The nasal cavity presents the expected aerated spaces between thin & even conchae and turbinates with smooth mucosal lining.

AGE

14 Years, 2 Months

Both temporomandibular joints present congruent joint spaces with even subchondral bone surfaces and are considered within normal limits.

INTERPRETED BY

Sebastian Schaub, DVM
 Dr. med. vet. DipECVDI

Both tympanic bullae are aerated, the mucosal lining is not seen, the bony wall is smooth and thin. The external ear canals are within normal limits.

HOSPITAL NAME

Neel Veterinary Hospital

The brain presents no deviation from normal anatomy and symmetry. The brain parenchyma is homogeneous and within normal limits for attenuation and distribution of contrast enhancement. The ventricular system is non-dilated and symmetric.

REFERRING VET

Dr. Deepan Kishore

The submandibular and medial retropharyngeal lymph nodes are small and elongated with a normal short-to-long-axis-ratio is < 0.5, the attenuation and contrast enhancement pattern is uniform.

In the subcutaneous tissue along the left lateral aspect of the neck and extending caudally up to the left scapula, a plaque like, multinodular mass is visible, presenting broad contact with the underlying musculature of the neck and left scapula. The mass is extending dorsally along the cranial thoracic spine up to the level of T1/T2. Contrast enhancing bands are emanating from the plaque like mass, extending between the muscle bellies of the neck and the left scapula. The mass is measuring approximately 5.4 x 8.4 x 11.6 cm in size.

INVOICE

53882

Thorax

Multifocal moderate spondylosis formation is seen along the thoracic spine. The periarticular bones of the right shoulder joint present mild to moderate osteophyte new bone formation.

A lipoma is seen in the left axillary region.

DATE

8-31-22

The sternal, cranial mediastinal and tracheobronchial lymph nodes are small elongated with a normal short-to-long-axis-ratio is < 0.5, the attenuation and contrast enhancement pattern is uniform and considered within normal limits.



PATIENT

The cardiovascular structures including the pulmonary vasculature are within normal limits.

River Sanders

Multiple well-defined soft tissue attenuating nodular lesions are seen multifocal throughout the lung parenchyma, measuring up to 5 mm in diameter. Sporadic punctuate mineralization of the lung parenchyma is appreciated.

SPECIES

Small incidental gas pockets are seen within the esophageal lumen, there is no evidence of abnormal dilation.

Canine

Abdomen

BREED

The serosal fat presents normal attenuation behavior. There is no evidence of peritoneal effusion or peritonitis.

Schnauzer/Miniature

Both kidneys present mild irregular margins. Multiple well-defined, spherical parenchymal filling defects are appreciated throughout the renal cortex bilaterally, measuring up to 5 mm in diameter.

SEX

The adrenal glands are within normal limits for size, shape and organ architecture.

Spayed Female

In the parenchyma of the caudal extremity of the spleen, an irregular marginated, fat attenuating region is visible.

AGE

Multifocal throughout the left hepatic lobes, post contrast heterogeneous hypo- to hyperattenuating roundish lesions are appreciated, measuring up to 4.0 cm in diameter. The hepatic volume is generalized moderately increased and the caudoventral hepatic margins are protruding beyond the costal arch; the gastric axis is deviated caudally.

14 Years, 2 Months

INTERPRETED BY

The pancreas is evenly contoured, the pancreatic parenchyma is homogeneous and presents uniform contrast enhancement.

Sebastian Schaub, DVM
Dr. med. vet. DipECVDI

The position, delineation, wall and content of the gastrointestinal tract are considered within normal limits throughout.

HOSPITAL NAME

Level with L5, an ovoid shaped, mild heterogeneous contrast enhancing nodule is attached to the left epaxial musculature. A subcutaneous nodular is seen dorsal to the sacrum.

Neel Veterinary
Hospital

COMPUTED TOMOGRAPHIC DIAGNOSIS

REFERRING VET

- Large plaque like subcutaneous mass along the left aspect of the neck and lateral aspect of the left scapula with invasive growth into the underlying musculature
- Soft tissue nodules lateral aspect left epaxial musculature and subcutaneous nodule dorsal to the sacrum
- Structured nodular interstitial lung pattern
- Hepatic intraparenchymal nodular lesions left liver lobes
- Periodontal abscess 309
- Advanced periodontal disease 201-203, 209
- Fat attenuating splenic parenchymal lesions – suspect myelolipomas
- Renal cysts
- Multiple absent teeth
- Lipoma left axillary region
- Degenerative osteoarthritis right shoulder joint
- Spondylosis deformans

Dr. Deepan Kishore

INVOICE

53882

DATE

8-31-22



PATIENT

River Sanders

SPECIES

Canine

BREED

Schnauzer/Miniature

SEX

Spayed Female

AGE

14 Years, 2 Months

INTERPRETED BY

Sebastian Schaub, DVM
Dr. med. vet. DipECVDI

HOSPITAL NAME

Neel Veterinary
Hospital

REFERRING VET

Dr. Deepan Kishore

INVOICE

53882

DATE

8-31-22

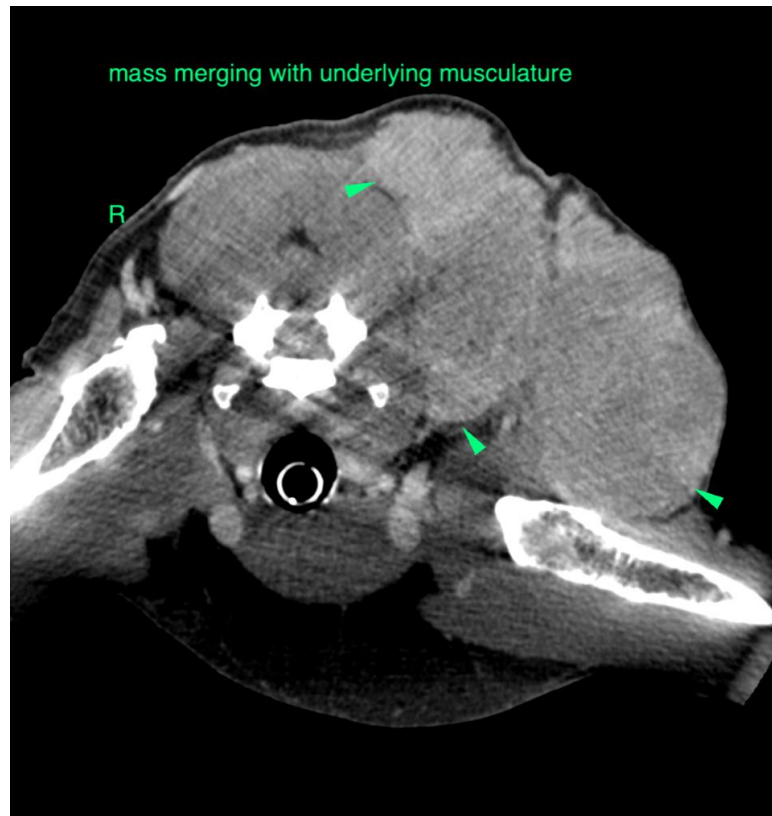
INTERPRETATION OF THE FINDINGS & FURTHER RECOMMENDATIONS

The large plaque like mass at the left aspect of the neck/shoulder region is consistent with the history of sarcoma. As the mass presents evidence of invasive growth into the underlying musculature curative surgery is not feasible, but the chances of debulking the mass in combination with adjuvant radiation therapy or chemotherapy might be discussed with oncologist.

The structured nodular lung pattern is compatible with pulmonary metastatic disease.

The nodular lesions along the soft tissues of the lumbar spine are concerning for metastatic disease as well.

The hepatic lesions can present large hepatic cysts, hepatic cystadenoma or malignant neoplastic transformation (e.g. carcinoma).





PATIENT

River Sanders

SPECIES

Canine

BREED

Schnauzer/Miniature

SEX

Spayed Female

AGE

14 Years, 2 Months

INTERPRETED BY

Sebastian Schaub, DVM
Dr. med. vet. DipECVDI

HOSPITAL NAME

Neel Veterinary
Hospital

REFERRING VET

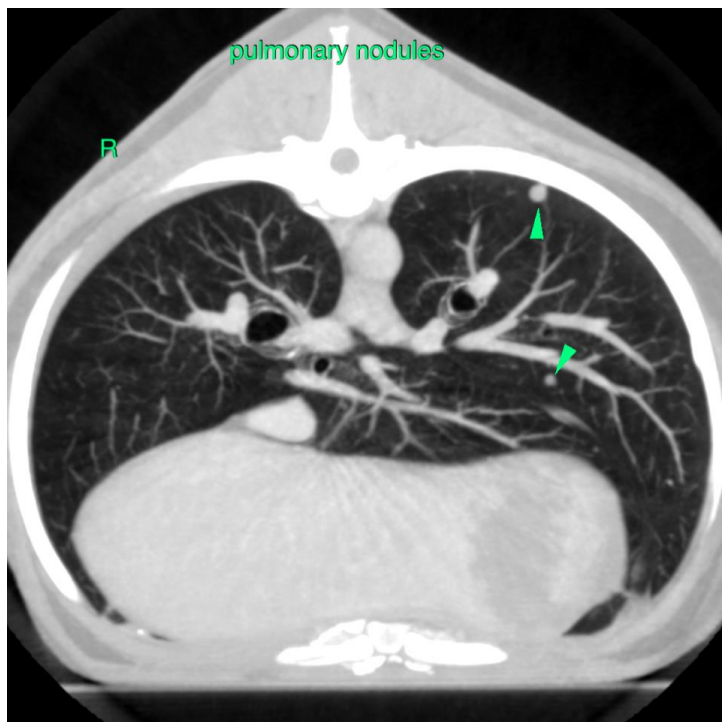
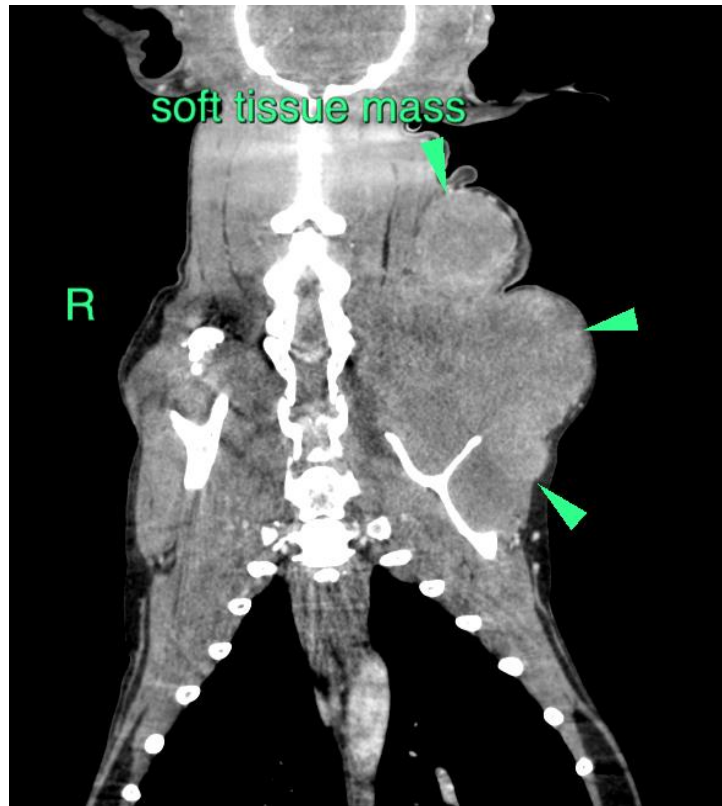
Dr. Deepan Kishore

INVOICE

53882

DATE

8-31-22





PATIENT

River Sanders

SPECIES

Canine

BREED

Schnauzer/Miniature

SEX

Spayed Female

AGE

14 Years, 2 Months

INTERPRETED BY

Sebastian Schaub, DVM
Dr. med. vet. DipECVDI

HOSPITAL NAME

Neel Veterinary
Hospital

REFERRING VET

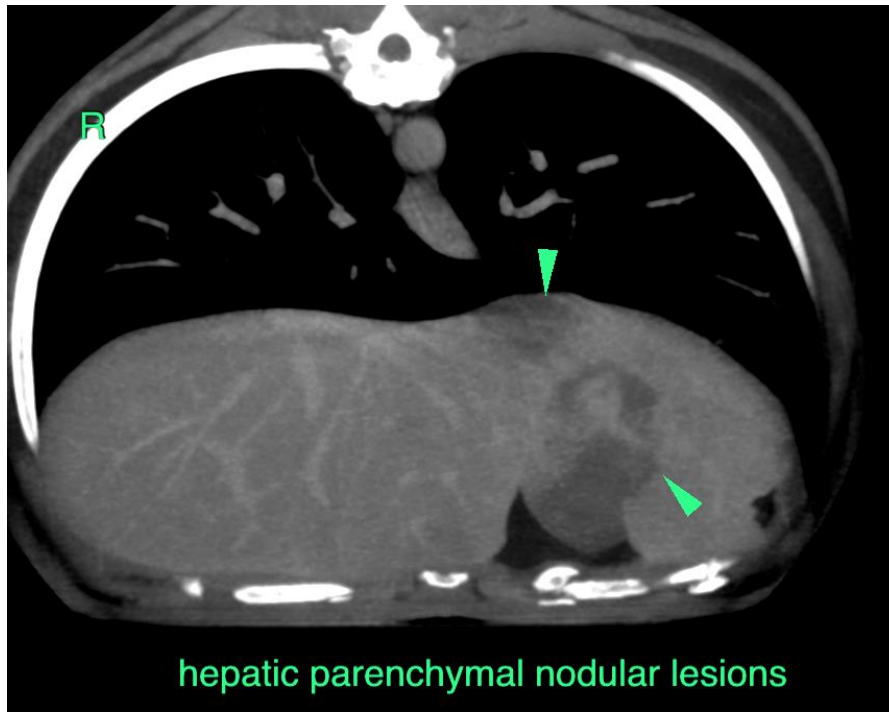
Dr. Deepan Kishore

INVOICE

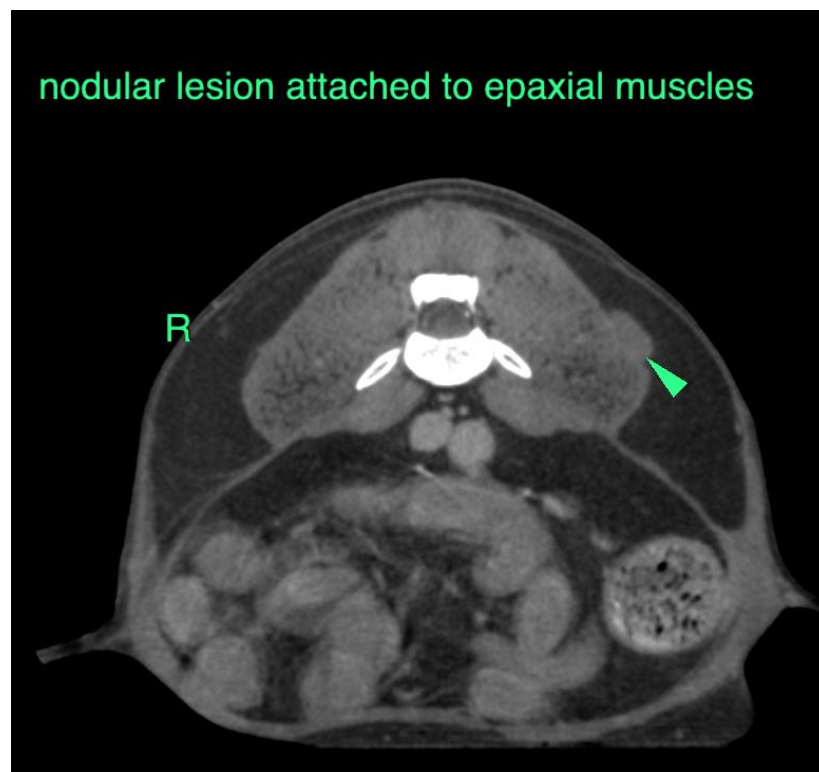
53882

DATE

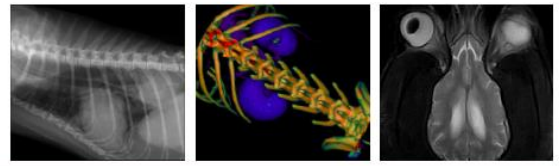
8-31-22



hepatic parenchymal nodular lesions



nodular lesion attached to epaxial muscles



PATIENT

River Sanders

The information and recommendations provided are based on the images presented by the referring veterinarian/sonographer. No evaluation can be communicated regarding pathology that was not visible in the image/video clips provided.

SPECIES

Canine

Thank you for this referral. If the clinical or image interpretation does not parallel your findings or if I can be of any further assistance please contact me.

BREED

Schnauzer/Miniature

Sebastian Schaub, Sebastian Schaub, DVM, Dr. med. vet. DipECVDI
sebast.schaub@gmail.com

SEX

Spayed Female

AGE

14 Years, 2 Months

INTERPRETED BY

Sebastian Schaub, DVM
Dr. med. vet. DipECVDI

HOSPITAL NAME

Neel Veterinary
Hospital

REFERRING VET

Dr. Deepan Kishore

INVOICE

53882

DATE

8-31-22