



PATIENT

Penelope Mieya

PRESENTING CLINICAL SIGNS

Waxing/waning swelling and lameness LF medial elbow, aspirates done at rdvm revealed nonseptic pyogranulomatous inflammation,

SPECIES

Canine

RADIOGRAPHIC STUDY OF THE ELBOW JOINTS

Radiographs of both elbow joints in two orthogonal imaging planes are provided for review.

BREED

Italian Greyhound

RADIOGRAPHIC FINDINGS

The periarticular bones of the right elbow joint present smooth osseous margins and no abnormalities of the surrounding soft tissue structures are appreciated.

At the proximal aspect of the anconeal process of the left elbow joint and lateral aspect of the radial head, mild osteophyte new bone formation is present. The left elbow joint presents mild to moderate periarticular swelling in the craniocaudal view.

SEX

Female Spayed

RADIOGRAPHIC DIAGNOSIS

- History of on/off swelling region of the left elbow joint
- Mild degenerative osteoarthritis left elbow joint
- Normal right elbow joint

AGE

6.67 Years

INTERPRETATION OF THE FINDINGS & FURTHER RECOMMENDATIONS

The swelling level with the left elbow joint has already been diagnosed inflammatory in origin and no additional cause is appreciated in the radiographic study of the elbow joints. An ultrasound examination of the respective region of the left front limb might reveal additional information of the genesis of the swelling.

The clinical relevance of the mild degenerative joint disease of the left elbow joint is unclear, a synovial tap can be considered in case of suspicion for active arthritis.

INTERPRETED BY

Sebastian Schaub, DVM
Dr. med. vet. DipECVDI

HOSPITAL NAME

Boca Park Animal
Hospital

REFERRING VET

Laura Warren

INVOICE

53825

DATE

8-30-22



PATIENT

Penelope Mieya

SPECIES

Canine

BREED

Italian Greyhound

SEX

Female Spayed

AGE

6.67 Years

INTERPRETED BY

Sebastian Schaub, DVM
Dr. med. vet. DipECVDI

HOSPITAL NAME

Boca Park Animal
Hospital

REFERRING VET

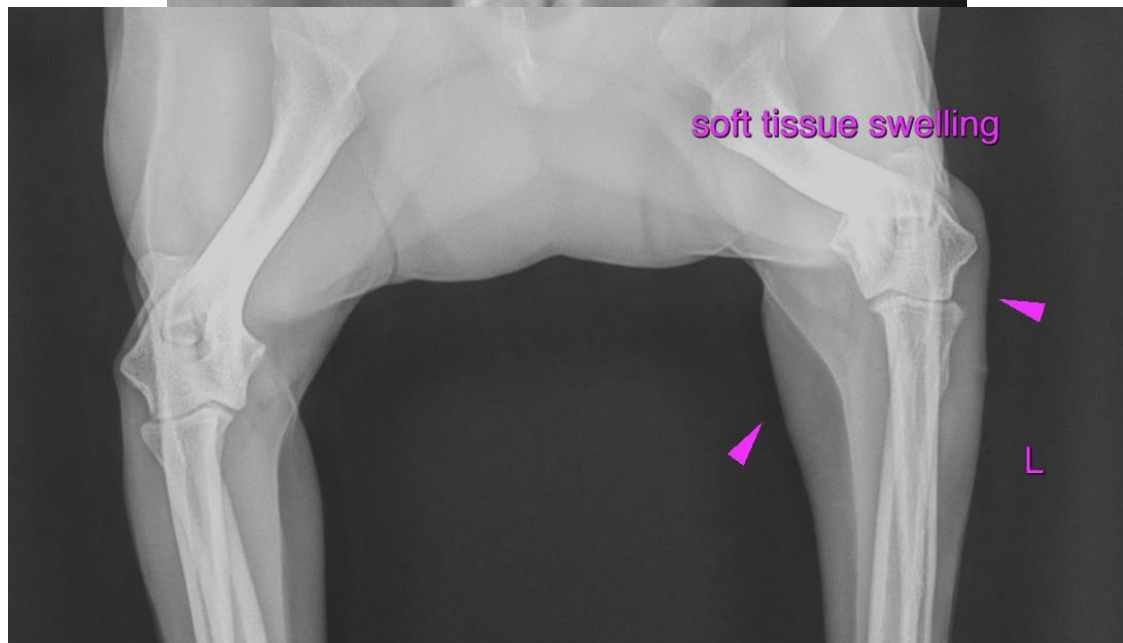
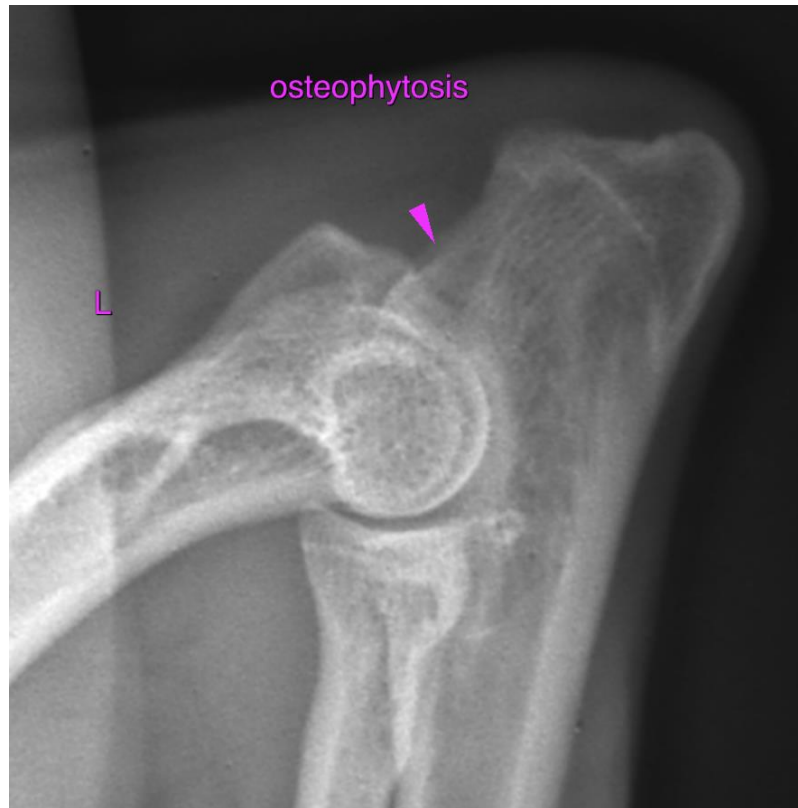Laura Warren

INVOICE

53825

DATE

8-30-22





PATIENT

Penelope Mieya

The information and recommendations provided are based on the images presented by the referring veterinarian/sonographer. No evaluation can be communicated regarding pathology that was not visible in the image/video clips provided.

Thank you for this referral. If the clinical or image interpretation does not parallel your findings or if I can be of any further assistance please contact me.

SPECIES

Canine

Sebastian Schaub, Sebastian Schaub, DVM, Dr. med. vet. DipECVDI
sebast.schaub@gmail.com

BREED

Italian Greyhound

SEX

Female Spayed

AGE

6.67 Years

INTERPRETED BY

Sebastian Schaub, DVM
Dr. med. vet. DipECVDI

HOSPITAL NAME

Boca Park Animal
Hospital

REFERRING VET

Laura Warren

INVOICE

53825

DATE

8-30-22