



**PATIENT PRESENTING CLINICAL SIGNS**

Charlie Simpson transient diabetic, hyperglycemia today with increased lung sounds and wheezing - more so on the right as compared to the left  
 Abnormal PE/Chem/CBC/UA Results: hyperglycemia, elevated ALP, Chol otherwise NSF on Chem/CBC

**SPECIES**

Feline

**RADIOGRAPHIC STUDY OF THE THORAX**

Radiographs of the thorax in two imaging planes are provided for review.

**BREED**

DSH

**RADIOGRAPHIC FINDINGS**

The body condition score is 7/9.

The vertebral endplates T13/L1 present mild spondylosis formation.

**SEX**

FS

The extrathoracic soft tissues present homogeneous without abnormalities.

The heart is of normal size and shape, there is no evidence of cardiac chamber or vascular enlargement. The pulmonary vasculature is within normal limits.

**AGE**

14 Years

The trachea is normal in diameter and presents the anticipated course. The luminal outline of the trachea is smooth.

The bronchial tree presents with thin walls and tapers uniformly towards the periphery as expected.

**INTERPRETED BY**

Sebastian Schaub, DVM  
 Dr. med. vet. DipECVDI

The lung parenchyma presents the expected architecture and generalized mild increased radiopacity, caused by an unstructured reticular pattern; the intrapulmonary vascular branching is seen up to the third order lung vessels.

**HOSPITAL NAME**

Petworks Veterinary Hospital

The diaphragm is well delineated with even surface and the expected mild cranial bulging of the diaphragmatic cupola.

**RADIOGRAPHIC DIAGNOSIS**

- Mild to moderate unstructured interstitial lung pattern

**REFERRING VET**

Dr Trudeau

**INTERPRETATION OF THE FINDINGS & FURTHER RECOMMENDATIONS**

The unstructured interstitial lung pattern is likely a sequela to the nutritional status and mild hypoinflation of the lung parenchyma. Non-specific differentials for an unstructured interstitial pattern include fibrosis, pneumonitis (inflammatory versus infectious), systemic disease (e.g. pancreatitis, IMHA, renal disease), neoplasia.

**INVOICE**

53823

**DATE**

8-30-22



**PATIENT**

Charlie Simpson

**SPECIES**

Feline

**BREED**

DSH

**SEX**

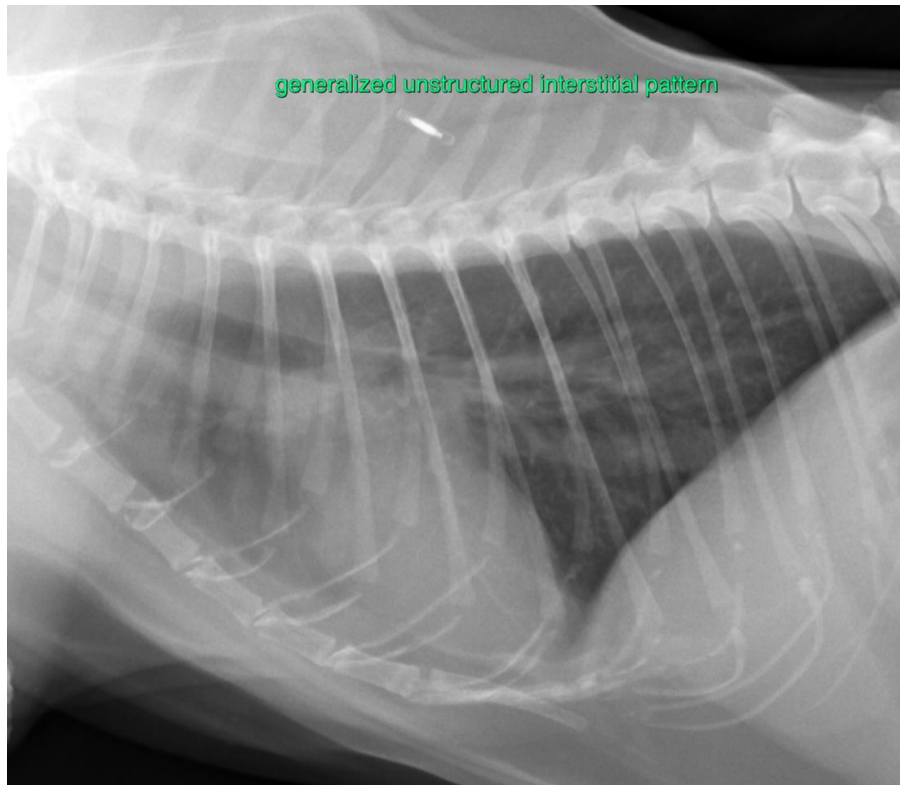
FS

**AGE**

14 Years

**INTERPRETED BY**

Sebastian Schaub, DVM  
Dr. med. vet. DipECVDI



**HOSPITAL NAME**

Petworks Veterinary  
Hospital

**REFERRING VET**

Dr Trudeau

**INVOICE**

53823

**DATE**

8-30-22

The information and recommendations provided are based on the images presented by the referring veterinarian/sonographer. No evaluation can be communicated regarding pathology that was not visible in the image/video clips provided.

Thank you for this referral. If the clinical or image interpretation does not parallel your findings or if I can be of any further assistance please contact me.

**Sebastian Schaub**, Sebastian Schaub, DVM, Dr. med. vet. DipECVDI  
sebast.schaub@gmail.com