



PATIENT PRESENTING CLINICAL SIGNS

Wednesday Last Hope Rescue
 History: T3-L3 myelopathy rule out deformity versus infectious. 2 days ago found puppy and O left Wednesday outside Dr, took her in and when they got here couldn't walk and now walk a litter better with help Eating drinking fine and bathroom is great Has a UTI Is going for laser treatment doing it once a day pred 5mg gaba 50mg BID clamox 150 BID

SPECIES

Canine

COMPUTED TOMOGRAPHIC STUDY OF THE ENTIRE SPINE

A high-resolution post-contrast CT study of the entire spine is provided for review.

BREED

Pitbull

COMPUTED TOMOGRAPHIC FINDINGS

The growth plates are age related visible.

SEX

Intact Female

The osseous and soft tissue structures of the cervic, thoracic, lumbar and sacral spine present without abnormalities. The intervertebral disc spaces have an even width. The vertebral endplates present without abnormalities.

COMPUTED TOMOGRAPHIC DIAGNOSIS

AGE

12 Weeks

- Normal spine

INTERPRETATION OF THE FINDINGS & FURTHER RECOMMENDATIONS

INTERPRETED BY

Sebastian Schaub,
 DVM Dr. med. vet.
 DipECVDI

The CT study of the spine presents without abnormalities, explaining the neurological deficits. Due to the acute onset of clinical signs, ischemic myelopathy (such as fibrocartilaginous embolism) might be a potential. If clinical signs are stationary or deteriorate again, consider complementing workup by MRI study of the spine.

TECHNICAL COMMENTS

HOSPITAL NAME

Animal Surgical
 Center-East Meadow

Recommend placing the patient in dorsal recumbency for evaluation of the spine, to avoid motion artefacts.

The information and recommendations provided are based on the images presented by the referring veterinarian/sonographer. No evaluation can be communicated regarding pathology that was not visible in the image/video clips provided.

REFERRING VET

Animal Health and
 Wellness Vet Office

Thank you for this referral. If the clinical or image interpretation does not parallel your findings or if I can be of any further assistance please contact me.

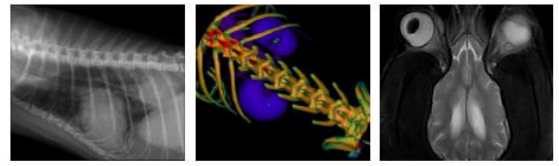
INVOICE

23768

Sebastian Schaub, Sebastian Schaub, DVM, Dr. med. vet. DipECVDI
 info@sonopath.com

DATE

8/3/23



PATIENT

Wednesday Last
Hope Rescue

SPECIES

Canine

BREED

Pitbull

SEX

Intact Female

AGE

12 Weeks

INTERPRETED BY

Sebastian Schaub,
DVM Dr. med. vet.
DipECVDI

HOSPITAL NAME

Animal Surgical
Center-East Meadow

REFERRING VET

Animal Health and
Wellness Vet Office

INVOICE

23768

DATE

8/3/23