



**PATIENT PRESENTING CLINICAL SIGNS**

Wally Barraza Wally presents today for slowing day and panting more often P has seemed to be slowing down and o's feel p is painful more often Described p has having "more bad days" than ever before P used to go on 30 min walks - now only can go for 5-10 minutes Pants during day and night sometimes, even with air conditioning on

**SPECIES**

Canine

**RADIOGRAPHIC STUDY OF THE THORACIC & LUMBAR SPINE**

Radiographs of the thoracic and lumbar spine in two orthogonal imaging planes are provided for review.

**BREED**

Poodle Mix

**RADIOGRAPHIC FINDINGS**

The intervertebral disc space T12/T13 is narrowed. The remainder of the osseous and surrounding soft tissue structures of the thoracic spine are within normal limits.

**SEX**

Male Neutered

Superimposed on the neuroforamina L2/L3 and L3/L4 mild heterogeneous mineralized material is appreciated. The remainder of the osseous and soft tissue structures of the lumbar spine are within normal limits.

**AGE**

12 Years

**RADIOGRAPHIC DIAGNOSIS**

- Mineralized material superimposed on neuroforamina L2/L3 nad L3/L4
- Discopathy T12/T13

**INTERPRETED BY**

Sebastian Schaub, DVM  
Dr. med. vet. DipECVDI

**INTERPRETATION OF THE FINDINGS & FURTHER RECOMMENDATIONS**

The mineralized material superimposed on the neuroforamina L2/I3 and L3/L4 can represent mineralized herniated disc material in the vertebral canal ± compressive myelopathy. Dystrophic mineralization of the superimposed soft tissues is a potential as well.

**HOSPITAL NAME**

DTLAvets

The narrowed intervertebral disc space T12/T13 can indicate discopathy that might or may not be associated with compressive myelopathy.

**REFERRING VET**

Dr. Montoya

**INVOICE**

59662

**DATE**

8-3-23



**PATIENT**

Wally Barraza

**SPECIES**

Canine

**BREED**

Poodle Mix

**SEX**

Male Neutered

**AGE**

12 Years

**INTERPRETED BY**

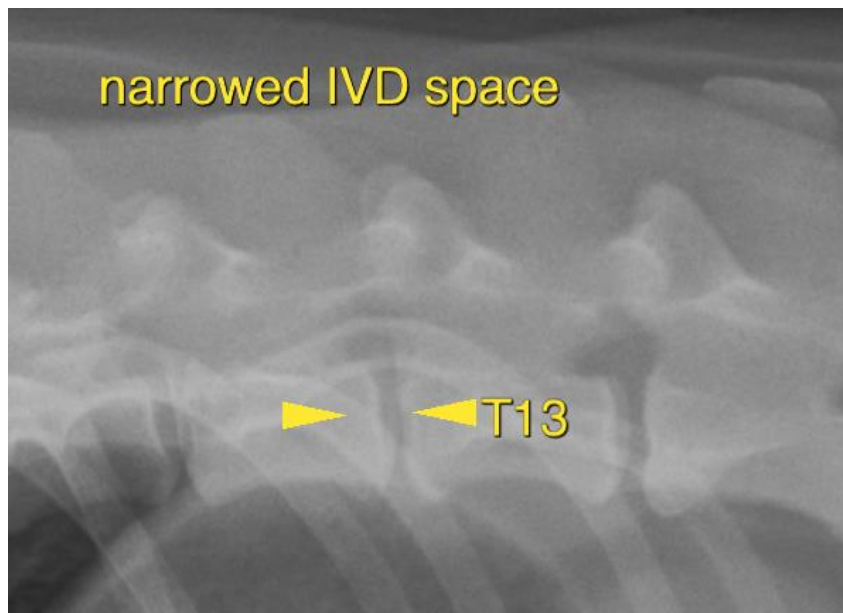
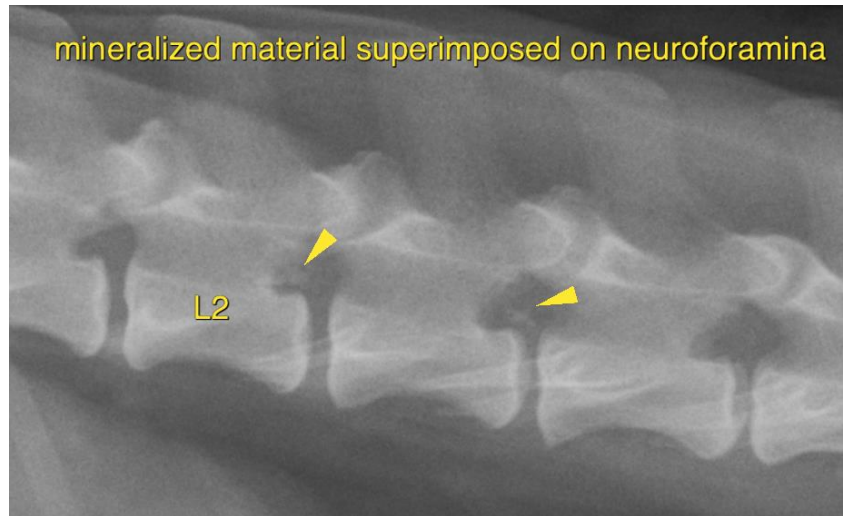
Sebastian Schaub, DVM  
Dr. med. vet. DipECVDI

**HOSPITAL NAME**

DTLAvets

**REFERRING VET**

Dr. Montoya



**INVOICE**

59662

The information and recommendations provided are based on the images presented by the referring veterinarian/sonographer. No evaluation can be communicated regarding pathology that was not visible in the image/video clips provided.

**DATE**

8-3-23

Thank you for this referral. If the clinical or image interpretation does not parallel your findings or if I can be of any further assistance please contact me.

**Sebastian Schaub**, Sebastian Schaub, DVM, Dr. med. vet. DipECVDI  
[info@sonopath.com](mailto:info@sonopath.com)