



**PATIENT PRESENTING CLINICAL SIGNS**

Bolt Cook 2 Weeks sneezing, reverse sneezing, inappetance, lethargy, weight loss, hypersalivation. Concern for soft palate pharyngeal dz, vs FB vs other  
Abnormal PE/Chem/CBC/UA Results: Culture pending, biopsy pending

**SPECIES COMPUTED TOMOGRAPHY OF THE SKULL**

Canine A pre- and post-contrast CT study of the skull in a bone and soft tissue reconstruction is provided for review.

**BREED COMPUTED TOMOGRAPHIC FINDINGS**

Malinois The pictured parts of the dentition are complete and unremarkable in all jaw quadrants.  
The nasal cavity presents the expected aerated spaces between thin & even conchae and turbinates with smooth mucosal lining.

**SEX**  
Male Both temporomandibular joints present congruent joint spaces with even subchondral bone surfaces and are considered within normal limits.

**AGE**  
3 Years Both tympanic bullae are aerated, the mucosal lining is not seen, the bony wall is smooth and thin. The external ear canals are within normal limits.

Level with the interventricular foramina of the ventricular system of the brain, a uniform soft tissue attenuating and heterogeneous contrast enhancing ovoidal shaped mass is appreciated, measuring 19 x 15 x 19 mm. The lateral ventricles are dilated. The interthalamic adhesion is distorted and has a decreased volume.

**INTERPRETED BY**

Sebastian Schaub, DVM  
Dr. med. vet. DipECVDI

The submandibular and medial retropharyngeal lymph nodes are small and elongated with a normal short-to-long-axis-ratio is < 0.5, the attenuation and contrast enhancement pattern is uniform.

**HOSPITAL NAME**

Western Veterinary  
Center

**COMPUTED TOMOGRAPHIC DIAGNOSIS**

- Intracranial extraaxial – intraventricular – strong contrast enhancing mass region of the interventricular foramina lateral ventricles
- Secondary obstructive hypertensive hydrocephalus internus

**REFERRING VET**

Dr. Crystal Gerards

**INTERPRETATION OF THE FINDINGS & FURTHER RECOMMENDATIONS**

The appreciated intraventricular mass is highly suggestive for extraaxial neoplasm – choroid plexus tumor is likely (papilloma versus carcinoma). A differential can be granuloma (e.g. mycotic, Toxoplasmosis, Leishmaniasis). Secondary hypertensive hydrocephalus internus.

**INVOICE**

59648

An underlying cause for the reverse sneezing is not appreciated.

**DATE**

8-3-23



**PATIENT**

Bolt Cook

**SPECIES**

Canine

**BREED**

Malinois

**SEX**

Male

**AGE**

3 Years

**INTERPRETED BY**

Sebastian Schaub, DVM  
Dr. med. vet. DipECVDI

**HOSPITAL NAME**

Western Veterinary  
Center

**REFERRING VET**

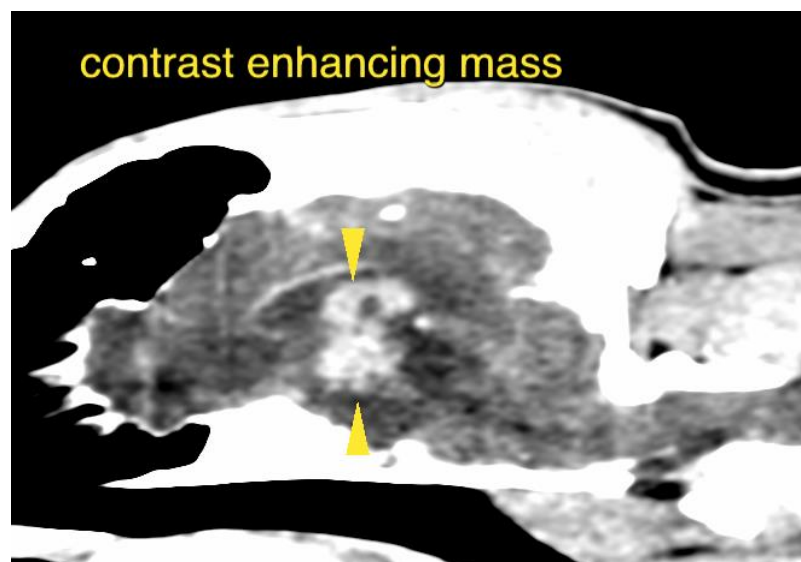
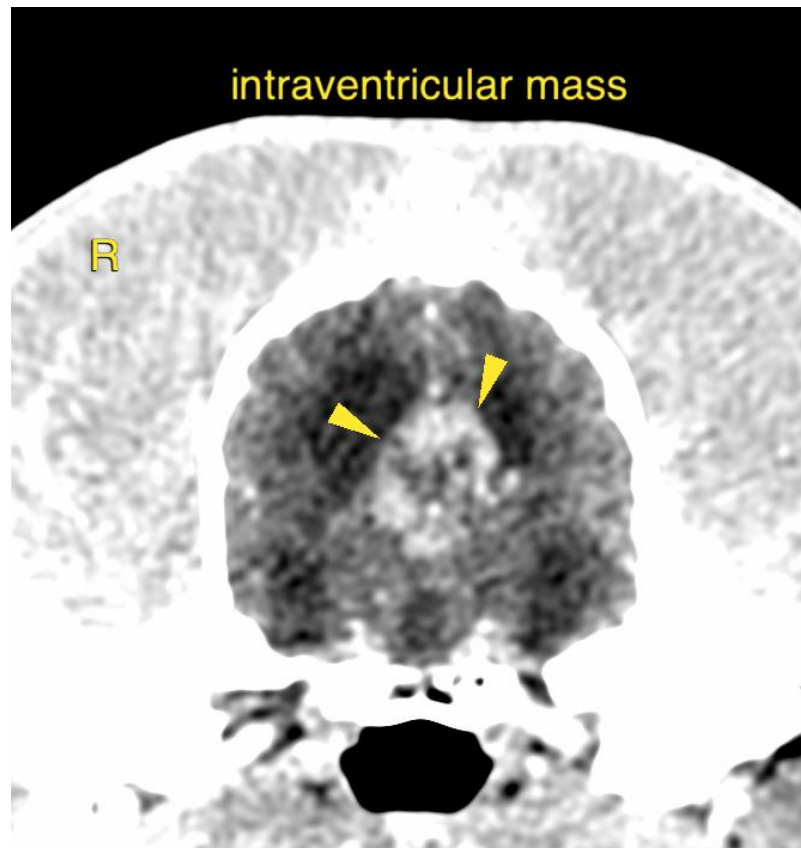
Dr. Crystal Gerards

**INVOICE**

59648

**DATE**

8-3-23





**PATIENT** The information and recommendations provided are based on the images presented by the referring veterinarian/sonographer. No evaluation can be communicated regarding pathology that was not visible in the image/video clips provided.  
Bolt Cook

Thank you for this referral. If the clinical or image interpretation does not parallel your findings or if I can be of any further assistance please contact me.

**SPECIES**

Canine **Sebastian Schaub**, Sebastian Schaub, DVM, Dr. med. vet. DipECVDI  
[info@sonopath.com](mailto:info@sonopath.com)

**BREED**

Malinois

**SEX**

Male

**AGE**

3 Years

**INTERPRETED BY**

Sebastian Schaub, DVM  
Dr. med. vet. DipECVDI

**HOSPITAL NAME**

Western Veterinary  
Center

**REFERRING VET**

Dr. Crystal Gerards

**INVOICE**

59648

**DATE**

8-3-23