



**PATIENT PRESENTING CLINICAL SIGNS**

Romeo Haines 5 yo MN Toy Poodle w history of multiple episodes of right vestibular dysfunction; (loss of balance, nystagmus). Exam findings: mild right head tilt and inducible positional nystagmus in dorsal recumbency, otherwise wnl. BW wnl; CSF: nucleated cell count=0, protein level pending, cytology normal.

**SPECIES**

Canine

Abnormal PE/Chem/CBC/UA Results: Exam findings: mild right head tilt and inducible positional nystagmus in dorsal recumbency, otherwise wnl. BW wnl; CSF: nucleated cell count=0, protein level pending, cytology normal.

**BREED**

Toy Poodle

**MAGNETIC RESONANCE IMAGING OF THE SKULL**

T2 weighted, FLAIR, SWI, diffusion weighted, T1 pre- and post-gadolinium sequence in multiple imaging planes are provided for review.

**MAGNETIC RESONANCE IMAGING FINDINGS**

**SEX**

MN

The brain presents the expected anatomy and bilateral symmetry with normal signal intensity and contrast enhancement. There is no evidence of abnormal meningeal enhancement.

The ventricular system presents the expected dimensions, morphology and the CSF signal is within normal limits in all sequences.

**AGE**

5 Years

The endolymph of the inner ear bilaterally is suppressed in FLAIR and no contrast enhancement of the inner ear is appreciated. The tympanic bullae are aerated, and the bony lining is thin. The right external ear canal presents a mildly narrowed right external ear canal.

**INTERPRETED BY**

Sebastian Schaub, DVM  
Dr. med. vet. DipECVDI

Surrounding soft tissue structures in the head region are within normal limits.

**MAGNETIC RESONANCE IMAGING DIAGNOSIS**

- Possible right sided otitis externa
- Normal brain
- Normal inner & middle ear

**HOSPITAL NAME**

Animal Health Partners

**INTERPRETATION OF THE FINDINGS & FURTHER RECOMMENDATIONS**

The MR study presents without macromorphological abnormalities, explaining the presenting clinical signs. The presumptive diagnosis can be idiopathic vestibular disease.

**REFERRING VET**

Dr. Stephanie Lovell

Check the right external ear canal for signs of otitis externa.

**INVOICE**

53240

**DATE**

8-3-22



**PATIENT**

Romeo Haines

**SPECIES**

Canine

**BREED**

Toy Poodle

**SEX**

MN

**AGE**

5 Years

**INTERPRETED BY**

Sebastian Schaub, DVM  
Dr. med. vet. DipECVDI

**HOSPITAL NAME**

Animal Health  
Partners

**REFERRING VET**

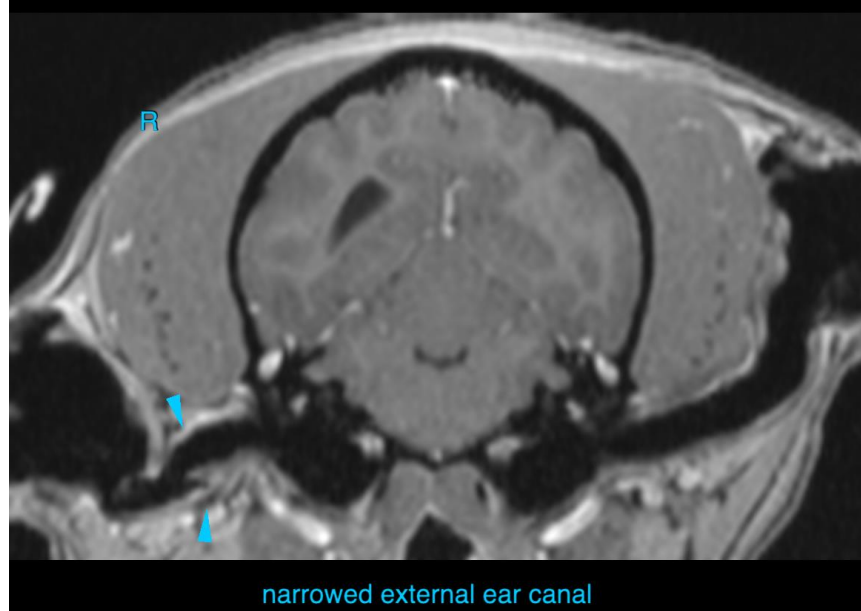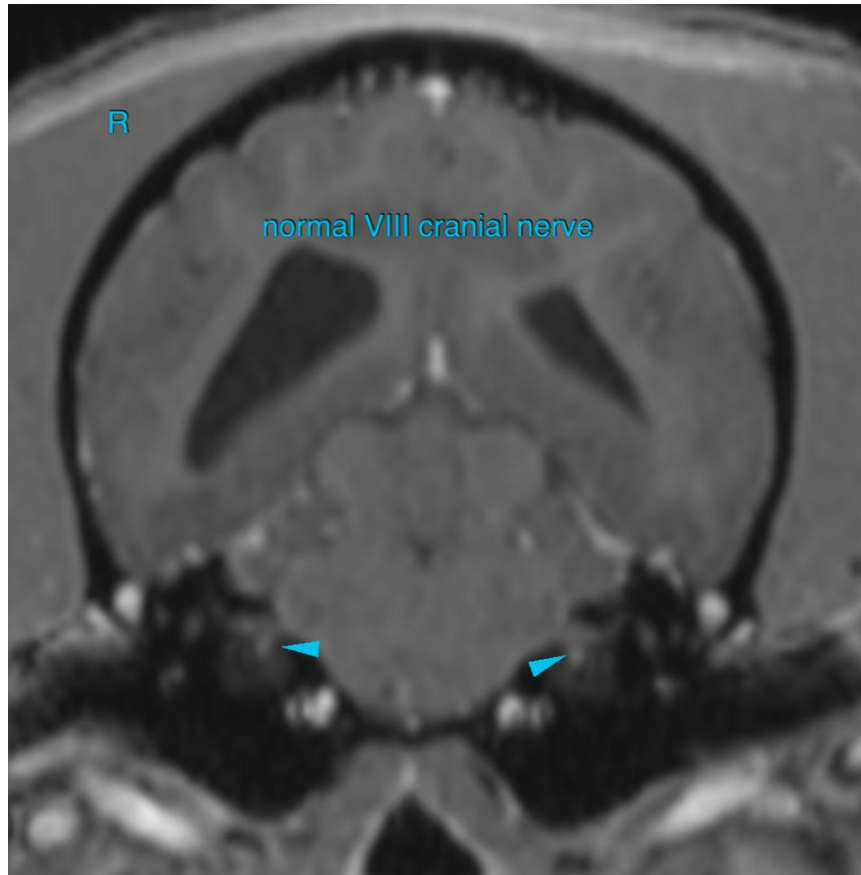
Dr. Stephanie Lovell

**INVOICE**

53240

**DATE**

8-3-22





**PATIENT**

Romeo Haines

The information and recommendations provided are based on the images presented by the referring veterinarian/sonographer. No evaluation can be communicated regarding pathology that was not visible in the image/video clips provided.

**SPECIES**

Canine

Thank you for this referral. If the clinical or image interpretation does not parallel your findings or if I can be of any further assistance please contact me.

**Sebastian Schaub**, Sebastian Schaub, DVM, Dr. med. vet. DipECVDI  
sebast.schaub@gmail.com

**BREED**

Toy Poodle

**SEX**

MN

**AGE**

5 Years

**INTERPRETED BY**

Sebastian Schaub, DVM  
Dr. med. vet. DipECVDI

**HOSPITAL NAME**

Animal Health  
Partners

**REFERRING VET**

Dr. Stephanie Lovell

**INVOICE**

53240

**DATE**

8-3-22