



PATIENT

Kaos Welch

PRESENTING CLINICAL SIGNS

Farm dog, limping on left front leg, we can see a broken toe, would like to make sure there are no other problems.

SPECIES

Canine

RADIOGRAPHIC STUDY OF THE FRONT LIMBS

A complete set of radiographs of the front limbs is provided for review.

BREED

Bermese Mountain Dog

The growth plates are age related open.

SEX

M

Both shoulder joints present smooth osseous margins and without abnormalities of the surrounding soft tissue structures.

The elbow joints bilaterally present well-defined osseous margins. The contour of the medial coronoid process of both elbow joints is well-defined.

AGE

6 Months

The distal metaphysis of the radius & ulna bilaterally presents with bilateral symmetric heterogeneous sclerosis of the bone and blurred margins.

The carpal joints bilaterally present without abnormalities.

The fourth digit of the left front limb presents with a homogeneous, moderate circumferential soft tissue swelling. The middle phalanx of the fourth digit presents with a well-defined short oblique fracture and a small (<2 mm) mineralized fragment at the axial aspect; there is mild lateral and proximal displacement of the distal segment.

INTERPRETED BY

Sebastian Schaub, DVM
Dr. med. vet. DipECVDI

RADIOGRAPHIC DIAGNOSIS

- Acute traumatic short oblique mid diaphyseal fracture middle phalanx fourth digit left front paw.
- Secondary moderate soft tissue swelling of the fourth digit left front paw
- Structural normal shoulder & elbow joints

HOSPITAL NAME

Sunridge Vet Clinic

INTERPRETATION OF THE FINDINGS & FURTHER RECOMMENDATIONS

The findings are fitting the history of fractured middle phalanx of the fourth digit of the left front paw – being a plausible explanation for the presenting clinical signs.

REFERRING VET

Dr. Magill

The mild heterogeneity and blurred margins of the distal metaphysis of the radius & ulna bilaterally is considered as normal osseous remodeling & cut-back zone of the growing bone.

INVOICE

53244

No additional clinically relevant pathologies are appreciated along both front limbs.

DATE

8-3-22



PATIENT

Kaos Welch

SPECIES

Canine

BREED

Bermese Mountain
Dog

SEX

M

AGE

6 Months

INTERPRETED BY

Sebastian Schaub, DVM
Dr. med. vet. DipECVDI

HOSPITAL NAME

Sunridge Vet Clinic

REFERRING VET

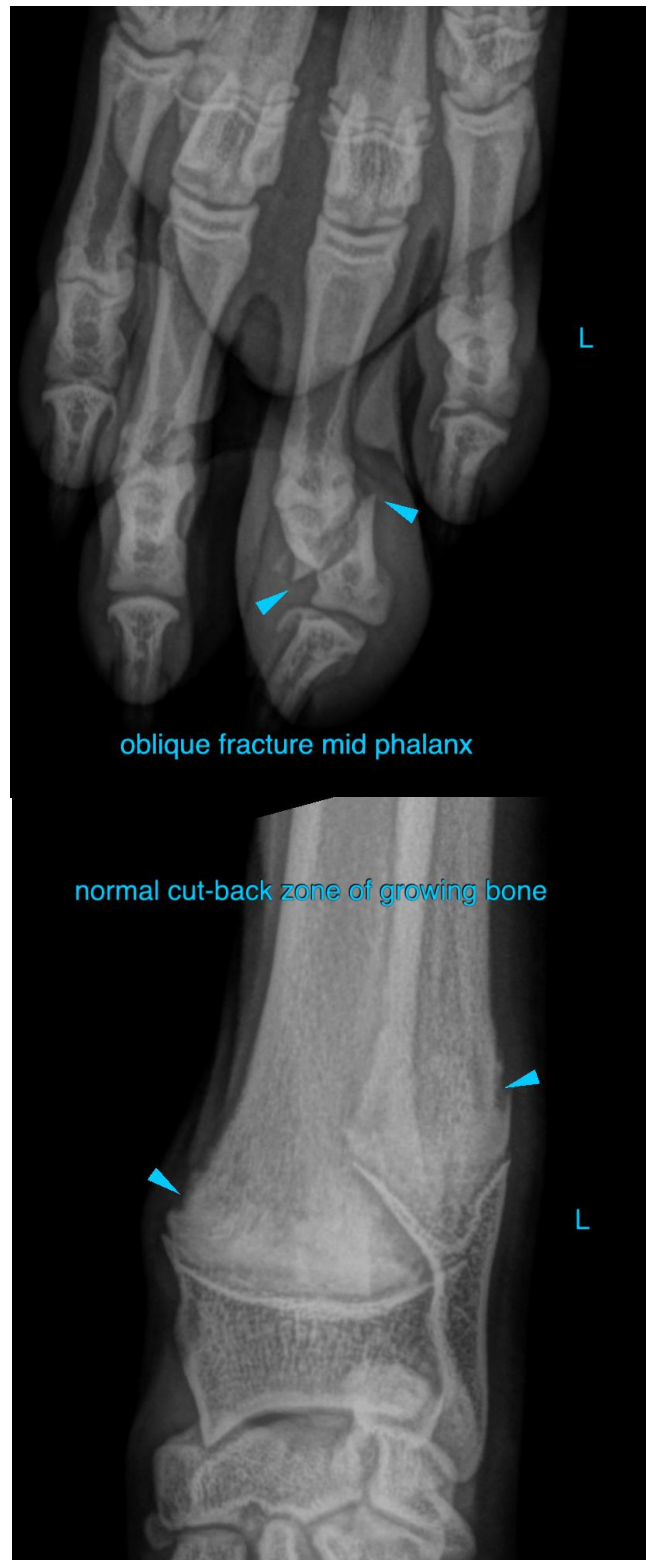
Dr. Magill

INVOICE

53244

DATE

8-3-22





PATIENT

Kaos Welch

SPECIES

Canine

The information and recommendations provided are based on the images presented by the referring veterinarian/sonographer. No evaluation can be communicated regarding pathology that was not visible in the image/video clips provided.

BREED

Bermese Mountain
Dog

Thank you for this referral. If the clinical or image interpretation does not parallel your findings or if I can be of any further assistance please contact me.

Sebastian Schaub, Sebastian Schaub, DVM, Dr. med. vet. DipECVDI
sebast.schaub@gmail.com

SEX

M

AGE

6 Months

INTERPRETED BY

Sebastian Schaub, DVM
Dr. med. vet. DipECVDI

HOSPITAL NAME

Sunridge Vet Clinic

REFERRING VET

Dr. Magill

INVOICE

53244

DATE

8-3-22