



**PATIENT PRESENTING CLINICAL SIGNS**

Bandit Rissler Pre-screen prior to mass removal. History of MCT-removed in 2019

**COMPUTED TOMOGRAPHY OF THE THORAX AND ABDOMEN**

**SPECIES** A high resolution pre- and post-contrast CT study of the abdomen and a post-contrast CT study of the thorax are provided for review.

Canine

**COMPUTED TOMOGRAPHIC FINDINGS**

**BREED** Thorax

Pitbull Mix In the subcutaneous tissue along the ventral thoracic wall, multiple, well-defined, ovoid shaped lipomas are seen, measuring up to 4.9 x 3.0 x 7.0 cm in size.

**SEX** In the subcutaneous tissue caudal to the right axillary region, a well-defined soft tissue attenuating nodule, measuring 14 mm in diameter is seen.

Male Neutered The sternal, cranial mediastinal and tracheobronchial lymph nodes are small elongated with a normal short-to-long-axis-ratio is < 0.5, the attenuation and contrast enhancement pattern is uniform and considered within normal limits.

**AGE** The cardiovascular structures including the pulmonary vasculature are within normal limits.

12 Years The bronchial tree presents with regular branching and tapers uniformly towards the periphery as expected, the bronchial walls are thin and smooth. The bronchus-to-artery ratio is within normal limits.

**INTERPRETED BY** Sebastian Schaub, DVM  
Dr. med. vet. DipECVDI The lung parenchyma presents the expected architecture and attenuation behavior with randomly interspersed punctuate mineralization. A zone with compression atelectasis of the caudodorsal aspects of the lung is seen.

**HOSPITAL NAME** Small incidental gas pockets are seen within the esophageal lumen, there is no evidence of abnormal dilation.

Catskill Veterinary Services, PLLC Abdomen

The serosal fat presents normal attenuation behavior. There is no evidence of peritoneal effusion or peritonitis.

**REFERRING VET** Both kidneys present within normal limits for size, shape and organ architecture. After contrast administration a bilaterally symmetric and uniform nephro- and pyelogram is noted.

Dr. Joseph D'Abbraccio The adrenal glands are within normal limits for size, shape and organ architecture.

**INVOICE** The liver presents with normal shape, even surface, uniformly attenuating parenchyma and homogeneous contrast enhancement, unremarkable.

53263 The common bile duct is mildly dilated, measuring 2.7 mm in diameter.

**DATE** In the caudal extremity of the spleen, a uniform soft tissue attenuating and mild heterogeneous contrast enhancing nodular parenchymal lesion is seen, measuring 2.3 cm in diameter and causes mild convex bulging of the splenic capsule at the same level. The remainder of the splenic parenchyma have a mild heterogeneous contrast enhancement pattern.

8-3-22



**PATIENT**

Bandit Rissler

The pancreas is evenly contoured, the pancreatic parenchyma is homogeneous and presents uniform contrast enhancement.

The position, delineation, wall and content of the gastrointestinal tract are considered within normal limits throughout.

**SPECIES**

Canine

Multiple intervertebral discs of the lumbar spine are mildly protruding into the vertebral canal, mildly distorting the ventral epidural space at the same level. Multifocal mild mineralization of the dural tube is appreciated. The lumbosacral intervertebral disc is mild to moderately protruding into the vertebral canal, occupying approximately up to 30% of the cross-sectional area of the vertebral canal at the same level. The vertebral endplates of the lumbosacral junction present moderate spondylosis formation.

**BREED**

Pitbull Mix

Both coxofemoral joints present mild osteophyte new bone formation.

**SEX**

Male Neutered

In the subcutaneous tissue at the dorsal aspect of the right gluteal region, a plaque like, uniform soft tissue attenuating and irregular contrast enhancing lesion is visible, measuring 40 x 7 x 40 mm in size.

**COMPUTED TOMOGRAPHIC DIAGNOSIS**

- Subcutaneous plaque like soft tissue mass right gluteal region
- Nodular splenic mass
- Non-specific subcutaneous nodule caudal to right axillary region
- Degenerative lumbosacral stenosis with possible dynamic compression of the cauda equina fibers
- Multifocal mild intervertebral disc protrusions lumbar spine
- Multiple subcutaneous lipomas along the ventral thoracic wall
- Degenerative osteoarthritis coxofemoral joints bilaterally
- Spondylosis deformans
- No evidence of pulmonary metastatic disease

**AGE**

12 Years

**INTERPRETED BY**

Sebastian Schaub, DVM  
Dr. med. vet. DipECVDI

**HOSPITAL NAME**

Catskill Veterinary  
Services, PLLC

**INTERPRETATION OF THE FINDINGS & FURTHER RECOMMENDATIONS**

The subcutaneous plaque like soft tissue lesion and the subcutaneous nodule caudal to the right axillary region are not-specific and further definition will warrant FNA sampling.

**REFERRING VET**

Dr. Joseph  
D'Abbraccio

Potentials for the splenic parenchymal nodule include nodular hyperplasia/regeneration nodule or neoplastic transformation. Ultrasound guided FNA sampling is warranted for further differentiation.

**INVOICE**

53263

**DATE**

8-3-22



**PATIENT**

Bandit Rissler

**SPECIES**

Canine

**BREED**

Pitbull Mix

**SEX**

Male Neutered

**AGE**

12 Years

**INTERPRETED BY**

Sebastian Schaub, DVM  
Dr. med. vet. DipECVDI

**HOSPITAL NAME**

Catskill Veterinary  
Services, PLLC

**REFERRING VET**

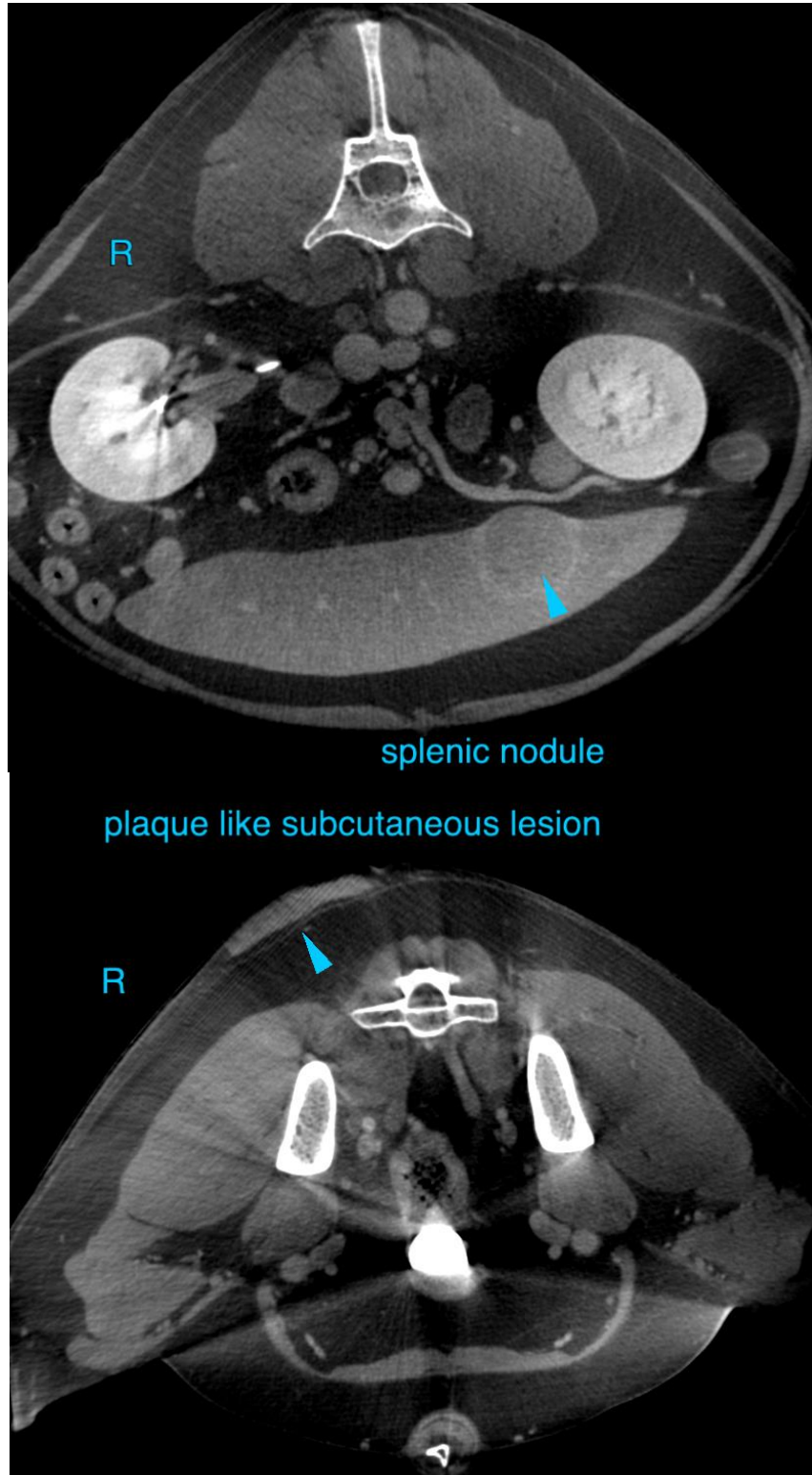
Dr. Joseph  
D'Abbraccio

**INVOICE**

53263

**DATE**

8-3-22





**PATIENT**

Bandit Rissler

**SPECIES**

Canine

**BREED**

Pitbull Mix

**SEX**

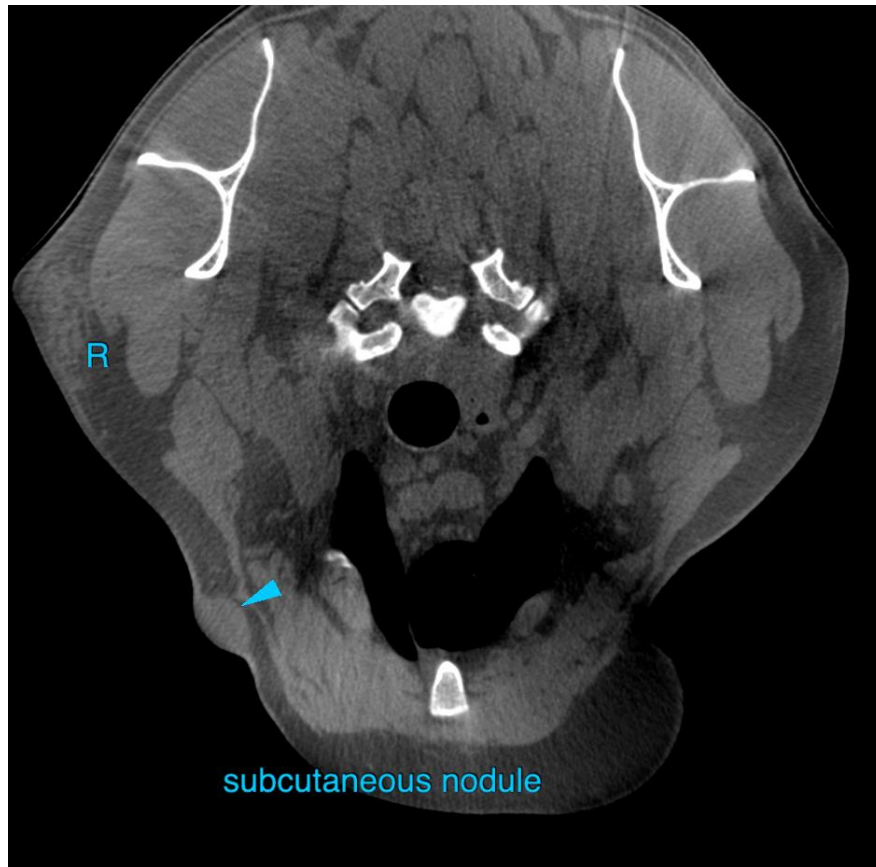
Male Neutered

**AGE**

12 Years

**INTERPRETED BY**

Sebastian Schaub, DVM  
Dr. med. vet. DipECVDI



**HOSPITAL NAME**

Catskill Veterinary  
Services, PLLC

**REFERRING VET**

Dr. Joseph  
D'Abbraccio

**INVOICE**

53263

**DATE**

8-3-22

The information and recommendations provided are based on the images presented by the referring veterinarian/sonographer. No evaluation can be communicated regarding pathology that was not visible in the image/video clips provided.

Thank you for this referral. If the clinical or image interpretation does not parallel your findings or if I can be of any further assistance please contact me.

**Sebastian Schaub**, Sebastian Schaub, DVM, Dr. med. vet. DipECVDI  
sebast.schaub@gmail.com