



**PATIENT PRESENTING CLINICAL SIGNS**

**PATIENT** Marlin Gough  
**SPECIES** History: Marlin, a 8 mo old Female Spayed Cane Corso, was presented to the Toronto Animal Health Partners Surgery Service for evaluation of a recent pelvic fracture. Marlin was hit by a truck two days prior to presentation. She went to Kawartha Emergency Hospital. She had pulmonary contusions and was on O2 for 48 hours and has since improved. She was not found to urinate on her own and had a urinary catheter in.

**CANINE** Canine  
 Abnormal PE/Chem/CBC/UA Results:

**BREED COMPUTED TOMOGRAPHIC STUDY OF THE PELVIS**

**CANE CORSO** A pre- and post-contrast CT study of the pelvis in a bone and soft tissue recon is provided for review.

**COMPUTED TOMOGRAPHIC FINDINGS**

**SEX** Spayed Female  
 The retroperitoneal and peritoneal fat present a mild to moderate soft tissue striation.

A moderate subcutaneous swelling and soft tissue striation is seen at the caudoventral aspect of the pelvis.

**AGE** 8 Months  
 The right iliac wing presents a serrated well-defined transverse fracture, level with the iliosacral joint with very mild medial deviation of the caudal segment of the right hemipelvis. A small (<3 mm) isolated osseous fragment is visible at the ventral aspect of the right ala ossis sacri.

**INTERPRETED BY** Sebastian Schaub, DVM Dr. med. vet. DipECVDI  
 A step formation is seen in the right femoral head, the epiphysis of the right femoral head is mildly displaced caudally and the physal plate is mildly irregular widened. A fissure line is running through the medial aspect of the femoral epiphysis. An isolated fragment, measuring 2 mm in size is visible at the medial aspect of the femoral neck.

**HOSPITAL NAME** Multiple fractures of the left aspect of the pelvic floor are seen.  
 Animal Health Partners  
 Pelvic symphysiolysis is present with mild overlapping of the osseous margins.  
 The left iliac wing presents a thin transverse fissure line level with the iliosacral joint.

**REFERRING VET COMPUTED TOMOGRAPHIC DIAGNOSIS**

- DR. LEA MEHRKENS**
- Salter Harris type III fracture right femoral head
  - Acute traumatic mildly displaced transverse fracture right iliac wing
  - Acute traumatic non-displaced fissure fracture left iliac wing
  - Multiple acute traumatic moderately displaced fractures floor of the left hemipelvis
  - Pelvic symphysiolysis
  - Mild narrowing of the pelvic canal
  - Hematoma formation level with the pelvic canal and retroperitonea space

**INVOICE**  
 12772

**DATE**  
 8/26/21



**PATIENT**

- No evidence of sacral fracture

Marlin Gough

**INTERPRETATION OF THE FINDINGS & FURTHER RECOMMENDATIONS**

Either conservative or surgical stabilization of the mildly displaced fracture of the right iliac wing can be considered here. Recommend surgical stabilization of the Salter Harris fracture of the right femoral head.

**SPECIES**

Canine

Conservative management of the remaining pelvic fractures is considered the therapy of choice.

**BREED**

Cane Corso

No overt abnormalities of the urinary bladder or urethra are appreciated but the hematoma formation in the pelvic canal. Pain might be the cause for dysuria.

**SEX**

Spayed Female

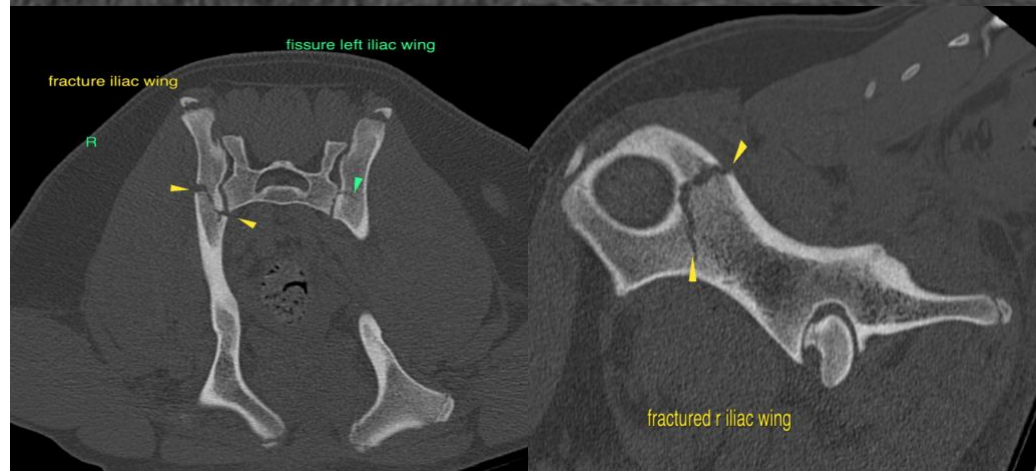
**AGE**

8 Months



**INTERPRETED BY**

Sebastian Schaub,  
DVM Dr. med. vet.  
DipECVDI



**HOSPITAL NAME**

Animal Health  
Partners

**REFERRING VET**

Dr. Lea Mehrkens

**INVOICE**

12772

The information and recommendations provided are based on the images presented by the referring veterinarian. No evaluation can be communicated regarding pathology that was not visible in the image/video clips provided.

**DATE**

8/26/21



**PATIENT**

Thank you for this referral. If the clinical or image interpretation does not parallel your findings or if I can be of any further assistance please contact me.

Marlin Gough

**Sebastian Schaub**, Sebastian Schaub, DVM, Dr. med. vet. DipECVDI  
[sebast.schaub@gmail.com](mailto:sebast.schaub@gmail.com)

**SPECIES**

Canine

**BREED**

Cane Corso

**SEX**

Spayed Female

**AGE**

8 Months

**INTERPRETED BY**

Sebastian Schaub,  
DVM Dr. med. vet.  
DipECVDI

**HOSPITAL NAME**

Animal Health  
Partners

**REFERRING VET**

Dr. Lea Mehrkens

**INVOICE**

12772

**DATE**

8/26/21