



**PATIENT PRESENTING CLINICAL SIGNS**

Zucchini Toyama History: Limping occasionally x 1 year. Physical exam findings: mild R forelimb lameness. Minimal decrease in R shoulder muscle mass compared to L. Crepitus and mild effusion in the R elbow. Normal shoulder. Patient very difficult to elicit pain response. HX or bilat TPLO

**SPECIES COMPUTED TOMOGRAPHIC STUDY OF THE RIGHT ELBOW JOINT**

Canine A high-resolution plain CT study of the right elbow joint is provided for review.

**BREED COMPUTED TOMOGRAPHIC FINDINGS**

Lab Mix The periarticular bones of the right elbow joint present moderate osteophyte new bone formation. The medial coronoid process of the right elbow joint is irregular marginated and has a heterogeneous density with a heterogeneous decreased density of the tip. A radio-ulnar step formation of 1.2 mm is present. The surrounding soft tissue structures of the right elbow joint are within normal limits.

**SEX**

Spayed Female **COMPUTED TOMOGRAPHIC DIAGNOSIS**

- Coronoid disease right elbow joint
- Degenerative osteoarthritis right elbow joint
- Very mild radio-ulnar step formation

**AGE**  
7 Years

**INTERPRETATION OF THE FINDINGS & FURTHER RECOMMENDATIONS**

**INTERPRETED BY** The degenerative joint disease of the right elbow joint is a sequela to underlying pathology of the medial coronoid process. Arthroscopy/arthrotomy can be performed to revise the right elbow joint.

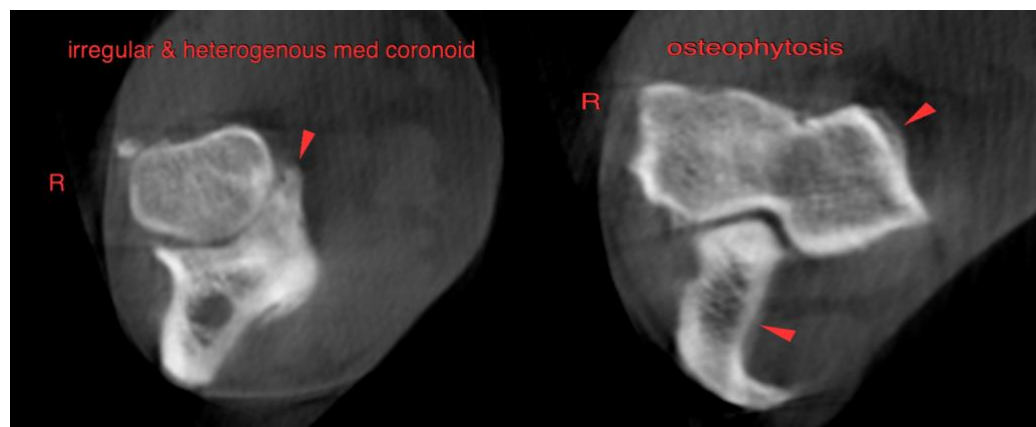
Sebastian Schaub,  
DVM Dr. med. vet.  
DipECVDI

**HOSPITAL NAME**

Southern Oregon VSC

**REFERRING VET**

Dr. Fugazzi



**INVOICE**

24061

The information and recommendations provided are based on the images presented by the referring veterinarian/sonographer. No evaluation can be communicated regarding pathology that was not visible in the image/video clips provided.

**DATE**

8/25/23



**PATIENT**

Thank you for this referral. If the clinical or image interpretation does not parallel your findings or if I can be of any further assistance please contact me.

Zucchini Toyama

**Sebastian Schaub**, Sebastian Schaub, DVM, Dr. med. vet. DipECVDI  
info@sonopath.com

**SPECIES**

Canine

**BREED**

Lab Mix

**SEX**

Spayed Female

**AGE**

7 Years

**INTERPRETED BY**

Sebastian Schaub,  
DVM Dr. med. vet.  
DipECVDI

**HOSPITAL NAME**

Southern Oregon VSC

**REFERRING VET**

Dr. Fugazzi

**INVOICE**

24061

**DATE**

8/25/23