

**PATIENT PRESENTING CLINICAL SIGNS**

Penut Rey History: Bile acid elevated (Post-96,2)

COMPUTED TOMOGRAPHIC STUDY OF THE ABDOMEN**SPECIES**

Canine

A high resolution pre- and post-contrast CT study of the abdomen is provided for review.

COMPUTED TOMOGRAPHIC FINDINGS**BREED**

Maltese

The serosal fat presents normal attenuation behavior. There is no evidence of peritoneal effusion or peritonitis.

Both kidneys present within normal limits for size, shape and organ architecture. After contrast administration a bilaterally symmetric and uniform nephro- and pyelogram is noted.

SEX

Neutered Male

The adrenal glands are within normal limits for size, shape and organ architecture.

Both liver and spleen present with normal shape, even surface, uniformly attenuating parenchyma and homogeneous contrast enhancement, unremarkable.

AGE

2 Years 4 Months

Approximately 40% of the gallbladder are occupied by mild mineralized biliary sludge.

The portal vein presents a normal order of its tributary veins and intrahepatic branching. No abnormal vessel is noted inside and outside of the liver parenchyma.

INTERPRETED BY

Sebastian Schaub, DVM
Dr. med. vet. DipECVDI

The pancreas is evenly contoured, the pancreatic parenchyma is homogeneous and presents uniform contrast enhancement.

HOSPITAL NAME

Mobile Pet Imaging

The position, delineation, wall and content of the gastrointestinal tract are considered within normal limits throughout.

The bony and surrounding soft tissue structures reveal no abnormalities.

REFERRING VET COMPUTED TOMOGRAPHIC DIAGNOSIS

Dr. Lorente

- No evidence of portosystemic shunting, neither intra- nor extrahepatic

INTERPRETATION OF THE FINDINGS & FURTHER RECOMMENDATIONS**INVOICE**

24052

No macroscopic vascular bypass of the liver was noted in the pre- and post-contrast studies of the abdomen. However, if the clinical signs are consistent with insufficiency of the liver primary non-cirrhotic portal hypertension (microvascular dysplasia) or other diffuse parenchymal liver disease would still be a potential and should be ruled out by means of ultrasound guided or surgical liver biopsy.

DATE

8/25/23



PATIENT

Penut Rey

SPECIES

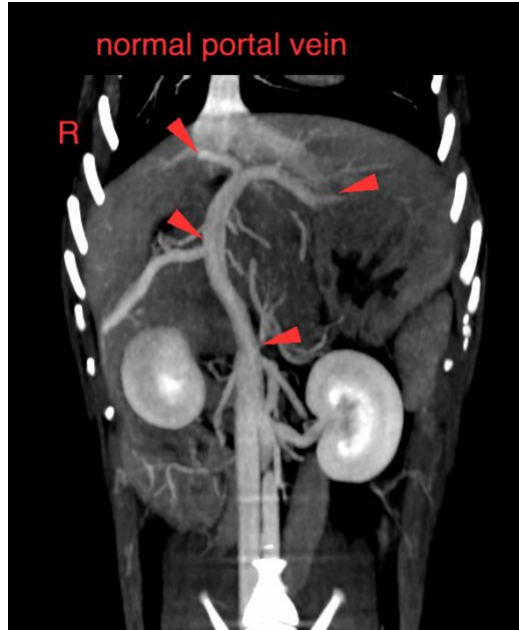
Canine

BREED

Maltese

SEX

Neutered Male



AGE

2 Years 4 Months

The information and recommendations provided are based on the images presented by the referring veterinarian/sonographer. No evaluation can be communicated regarding pathology that was not visible in the image/video clips provided.

INTERPRETED BY

Sebastian Schaub, DVM
Dr. med. vet. DipECVDI

Thank you for this referral. If the clinical or image interpretation does not parallel your findings or if I can be of any further assistance please contact me.

Sebastian Schaub, Sebastian Schaub, DVM, Dr. med. vet. DipECVDI
info@sonopath.com

HOSPITAL NAME

Mobile Pet Imaging

REFERRING VET

Dr. Lorente

INVOICE

24052

DATE

8/25/23