



PATIENT PRESENTING CLINICAL SIGNS

Reyna Cruz Persistent cough for one month

COMPUTED TOMOGRAPHY OF THE NECK AND THORAX

SPECIES A high resolution pre- and post-contrast CT study of the neck and thorax are provided for review.

Canine **COMPUTED TOMOGRAPHIC FINDINGS**

Neck

BREED Both tympanic bullae are aerated, the mucosal lining is not seen, the bony wall is smooth and thin. The external ear canals are within normal limits.

Chihuahua The submandibular and medial retropharyngeal lymph nodes are small and elongated with a normal short-to-long-axis-ratio is < 0.5, the attenuation and contrast enhancement pattern is uniform.

SEX The larynx reveals no abnormalities.

Female The osseous and soft tissue structures of the neck are unremarkable.

Thorax

AGE The bony and surrounding soft tissue structures are within normal limits.

11 Years The sternal, cranial mediastinal and tracheobronchial lymph nodes are small elongated with a normal short-to-long-axis-ratio is < 0.5, the attenuation and contrast enhancement pattern is uniform and considered within normal limits.

INTERPRETED BY

Sebastian Schaub, DVM
Dr. med. vet. DipECVDI

The cardiovascular structures including the pulmonary vasculature are within normal limits.

The bronchial tree presents with regular branching and tapers uniformly towards the periphery as expected, the bronchial walls are thin and smooth. The bronchus-to-artery ratio is within normal limits.

HOSPITAL NAME

Mobile Pet Imaging

The lung parenchyma presents the expected architecture and attenuation behavior with randomly distributed interspersed punctuate mineralization.

Small incidental gas pockets are seen within the esophageal lumen, there is no evidence of abnormal dilation.

REFERRING VET

Lorente

COMPUTED TOMOGRAPHIC DIAGNOSIS

- Normal neck
- Normal thorax, but sporadic pulmonary osteomas

INVOICE

59944

INTERPRETATION OF THE FINDINGS & FURTHER RECOMMENDATIONS

The CT study of the neck and the thorax presents without abnormalities, an underlying cause for the cough cannot be specified. However, this does not rule out potential underlying tracheitis or bronchitis entirely. Workup might be complementing by bronchoscopy including BAL for further definition.

DATE

8-24-23



PATIENT

Reyna Cruz

SPECIES

Canine

BREED

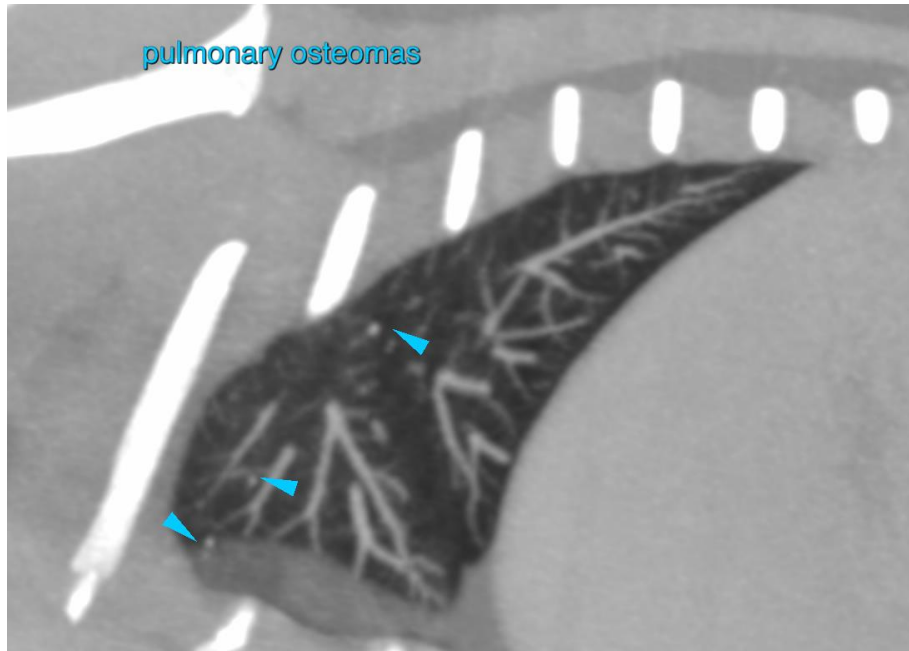
Chihuahua

SEX

Female

AGE

11 Years



INTERPRETED BY

Sebastian Schaub, DVM
Dr. med. vet. DipECVDI

The information and recommendations provided are based on the images presented by the referring veterinarian/sonographer. No evaluation can be communicated regarding pathology that was not visible in the image/video clips provided.

Thank you for this referral. If the clinical or image interpretation does not parallel your findings or if I can be of any further assistance please contact me.

HOSPITAL NAME

Mobile Pet Imaging

Sebastian Schaub, Sebastian Schaub, DVM, Dr. med. vet. DipECVDI
info@sonopath.com

REFERRING VET

Lorente

INVOICE

59944

DATE

8-24-23