



**PATIENT PRESENTING CLINICAL SIGNS**

Lucky Kurgan oral mass noted on physical exam

**COMPUTED TOMOGRAPHY OF THE SKULL & THORAX**

**SPECIES** A high resolution pre- and post-contrast CT study of the skull and a post contrast CT-study of the thorax are provided for review.

Canine

**COMPUTED TOMOGRAPHIC FINDINGS**

**BREED** Skull

Poodle Triadan 101, 105, 202, 206, 301 are absent. The roots of triadan 108 present resorptive lesions.

The alveolar bone starting distal to triadan 104 up to the level of 106 presents an ill-defined zone with moth eaten osteolysis of the right maxillary bone and accompanying amorphous new bone formation at the same level, perforating the nasal cavity. The horizontal plate of the right palatine bone at the same level presents with immature periosteal new bone formation.

**SEX**

Male Neutered

The nasal cavity presents the expected aerated spaces between thin & even conchae and turbinates with smooth mucosal lining.

**AGE**

10 Years

Both temporomandibular joints present congruent joint spaces with even subchondral bone surfaces and are considered within normal limits.

Both tympanic bullae are aerated, the mucosal lining is not seen, the bony wall is smooth and thin. The external ear canals are within normal limits. In the subcutaneous tissue rostral to the left pinna, an ovoid shaped, well-defined lipoma is seen, measuring 2.3 x 0.8 x 3.0 cm.

**INTERPRETED BY**

Sebastian Schaub, DVM  
Dr. med. vet. DipECVDI

The brain presents no deviation from normal anatomy and symmetry. The brain parenchyma is homogeneous and within normal limits for attenuation and distribution of contrast enhancement. The ventricular system is non-dilated and symmetric.

**HOSPITAL NAME**

Mobile Pet Imaging

The right mandibular lymph nodes are prominent.

Thorax

The vertebral endplates C6/C7 and T12/T13 present mild spondylosis formation.

**REFERRING VET**

Lorente

The sternal, cranial mediastinal and tracheobronchial lymph nodes are small elongated with a normal short-to-long-axis-ratio is < 0.5, the attenuation and contrast enhancement pattern is uniform and considered within normal limits.

**INVOICE**

59907

The cardiovascular structures including the pulmonary vasculature are within normal limits.

The bronchial tree presents with regular branching and tapers uniformly towards the periphery as expected, the bronchial walls are thin and smooth. The bronchus-to-artery ratio is within normal limits.

**DATE**

8-24-23

The lung parenchyma presents the expected architecture and attenuation behavior with randomly distributed interspersed punctuate mineralization.

Small incidental gas pockets are seen within the esophageal lumen, there is no evidence of abnormal dilation.


**PATIENT COMPUTED TOMOGRAPHIC DIAGNOSIS**

- Lucky Kurgan**
- Polyostotic aggressive mixed osteoproliferative and osteolytic lesion right maxillary bone, level with triadan 104 to 106
  - Lymphadenopathy right mandibular lymph nodes
- SPECIES**
- Subcutaneous lipoma rostral aspect base of left pinna
  - Dental resorptive lesions 108
- Canine**
- Multiple absent teeth
  - Spondylosis deformans
  - No evidence of pulmonary metastatic disease

**BREED**

Poodle

**SEX**

Male Neutered

**INTERPRETATION OF THE FINDINGS & FURTHER RECOMMENDATIONS**

The appreciated aggressive bone lesion of the rostral segment of the right maxillary bone is compatible with neoplastic transformation. Differentials include osteosarcoma, chondrosarcoma, squamous cell carcinoma, fibrosarcoma, melanoma, other. FNA sampling and or biopsy can be performed for further differentiation. Complete surgical excision via bilateral rostral hemimaxillectomy appears feasible.

Recommend FNA sampling of the right mandibular lymph nodes to rule out metastatic disease.

**AGE**

10 Years

**INTERPRETED BY**

 Sebastian Schaub, DVM  
 Dr. med. vet. DipECVDI

**HOSPITAL NAME**

Mobile Pet Imaging

**REFERRING VET**

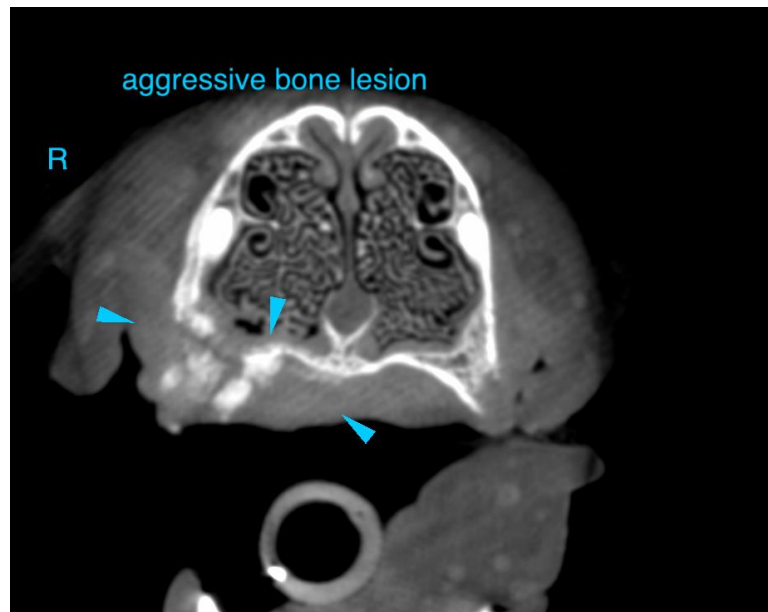
Lorente

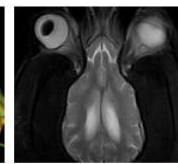
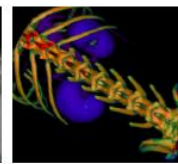
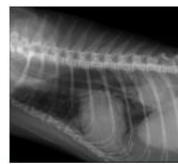
**INVOICE**

59907

**DATE**

8-24-23





**PATIENT**

Lucky Kurgan

**SPECIES**

Canine

**BREED**

Poodle

**SEX**

Male Neutered

**AGE**

10 Years

**INTERPRETED BY**

Sebastian Schaub, DVM  
Dr. med. vet. DipECVDI

**HOSPITAL NAME**

Mobile Pet Imaging

**REFERRING VET**

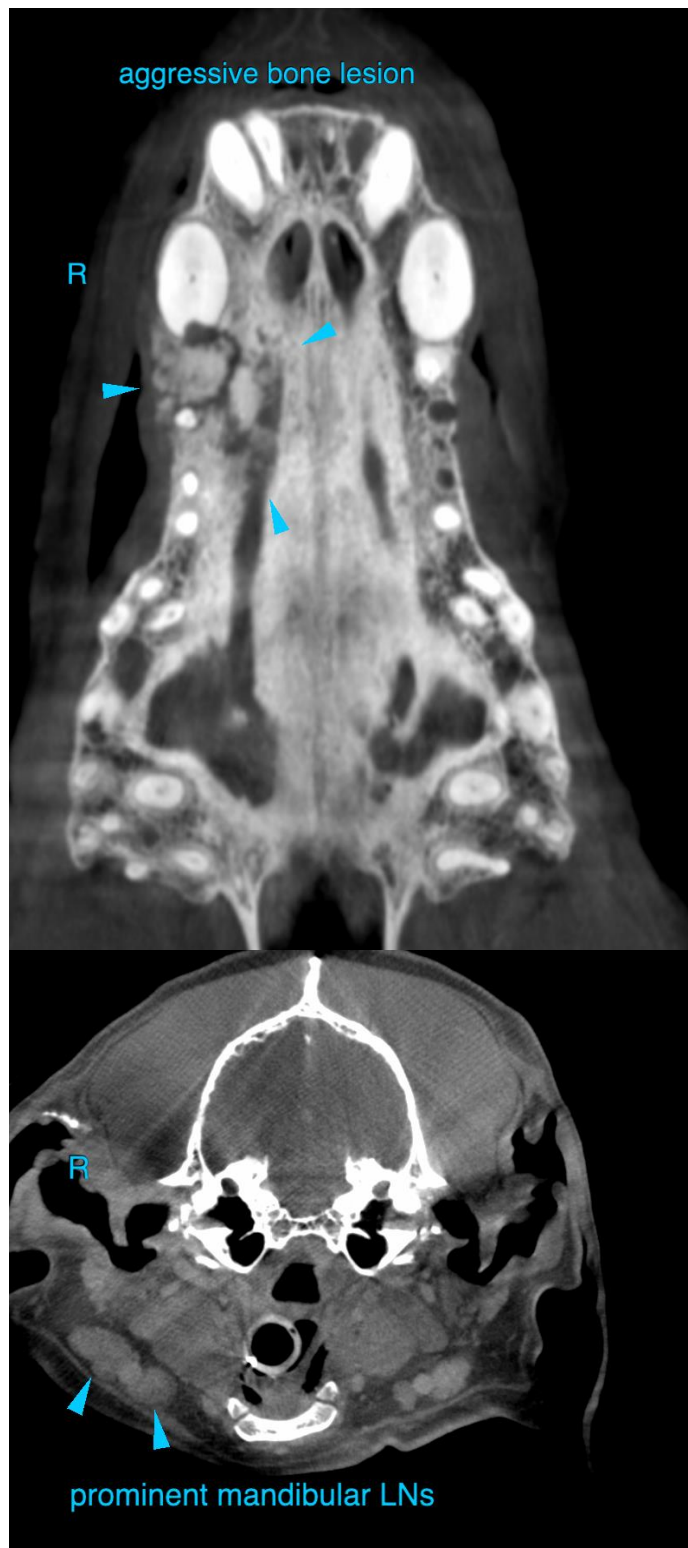Lorente

**INVOICE**

59907

**DATE**

8-24-23



**PATIENT**

Lucky Kurgan

The information and recommendations provided are based on the images presented by the referring veterinarian/sonographer. No evaluation can be communicated regarding pathology that was not visible in the image/video clips provided.

**SPECIES**

Canine

Thank you for this referral. If the clinical or image interpretation does not parallel your findings or if I can be of any further assistance please contact me.

**BREED**

Poodle

**Sebastian Schaub**, Sebastian Schaub, DVM, Dr. med. vet. DipECVDI  
[info@sonopath.com](mailto:info@sonopath.com)

**SEX**

Male Neutered

**AGE**

10 Years

**INTERPRETED BY**

Sebastian Schaub, DVM  
Dr. med. vet. DipECVDI

**HOSPITAL NAME**

Mobile Pet Imaging

**REFERRING VET**

Lorente

**INVOICE**

59907

**DATE**

8-24-23