



PATIENT PRESENTING CLINICAL SIGNS

Flipflop Barnaby hind leg paralysis

COMPUTED TOMOGRAPHY OF THE CERVICAL, THORACIC AND LUMBAR SPINE

SPECIES A high resolution myelographic CT study of the entire spine is provided for review.

Canine **COMPUTED TOMOGRAPHIC FINDINGS**

The contrast media is distributing along the epidural space.

BREED The intervertebral disc C2/C3 is bulging into the left ventral aspect of the vertebral canal, distorting the dural tube at the same level.

Mix Breed The remainder of the osseous and soft tissue structures of the cervical spine are within normal limits.

SEX T13 presents a rib at the left aspect and transverse process at the right aspect. The right aspect of the vertebral body, the right pedicle and the right lamina of T13 present advanced permeative osteolysis with an associated soft tissue mass. The soft tissue mass of T13 is bulging into the vertebral canal, occupying approximately 60% of the cross-sectional area of the vertebral canal at the same level. The dural tube level T13 is displaced to the left and compressed.

AGE The remainder of the osseous and soft tissue structures of the thoracic spine are within normal limits.

10 Years The lumbosacral intervertebral disc is bulging into the vertebral canal, occupying approximately 30% of the cross-sectional area of the vertebral canal at the same level. The remainder of the osseous and soft tissue structures of the lumbar spine are within normal limits.

INTERPRETED BY

Sebastian Schaub, DVM
Dr. med. vet. DipECVDI

The right humeral head and the right tabula of the os ischium present an ill-defined zone with permeative osteolysis.

The right medial retropharyngeal, right superficial cervical and the renal lymph nodes bilaterally are enlarged and rounded.

HOSPITAL NAME

Animal Surgical
Center - Oceanside

COMPUTED TOMOGRAPHIC DIAGNOSIS

- Polyostotic aggressive osteolytic lesions T13, right humerus and right os ischium
- T13 is associated with a soft tissue mass and secondary compressive myelopathy
- Lymphadenopathy right medial retropharyngeal, right superficial cervical and renal lymph nodes
- Intervertebral disc protrusion C2/C3 with potential myelocompression
- Intervertebral disc protrusion L7/S1 without compressive myelopathy
- Thoracolumbar transitional vertebra T13

REFERRING VET

All Creatures
Veterinary Services

INVOICE INTERPRETATION OF THE FINDINGS & FURTHER RECOMMENDATIONS

59904 The neurological deficits can be explained by the aggressive bone lesion T13. Due to the polyostotic aggressive lesions and the lymphadenopathy of multiple lymph nodes, the odds for underlying round cell tumor, such as myeloma/plasmocytoma, lymphosarcoma, histiocytic sarcoma are high. Ultrasound guided FNA sampling of the enlarged lymph nodes ± T13 can be performed for further definition.

DATE

8-24-23



PATIENT

Flipflop Barnaby

SPECIES

Canine

BREED

Mix Breed

SEX

Female

AGE

10 Years

INTERPRETED BY

Sebastian Schaub, DVM
Dr. med. vet. DipECVDI

HOSPITAL NAME

Animal Surgical
Center - Oceanside

REFERRING VET

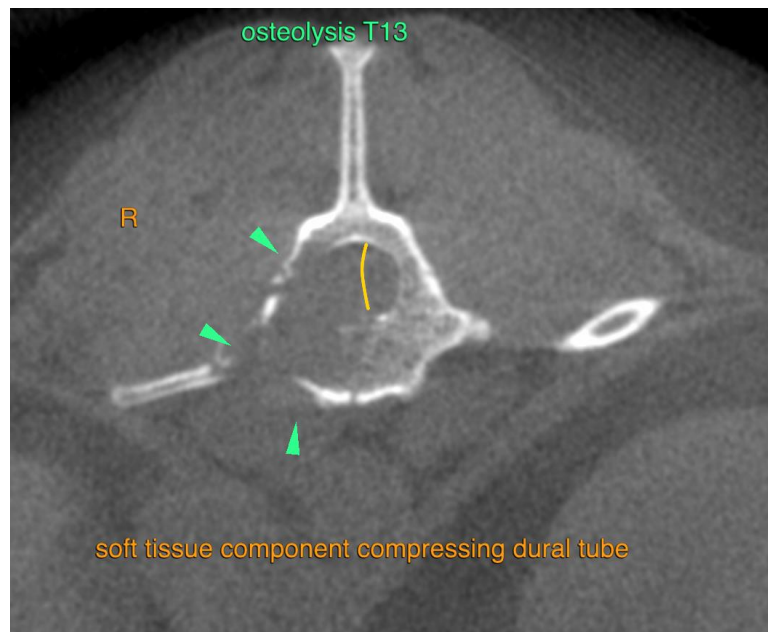
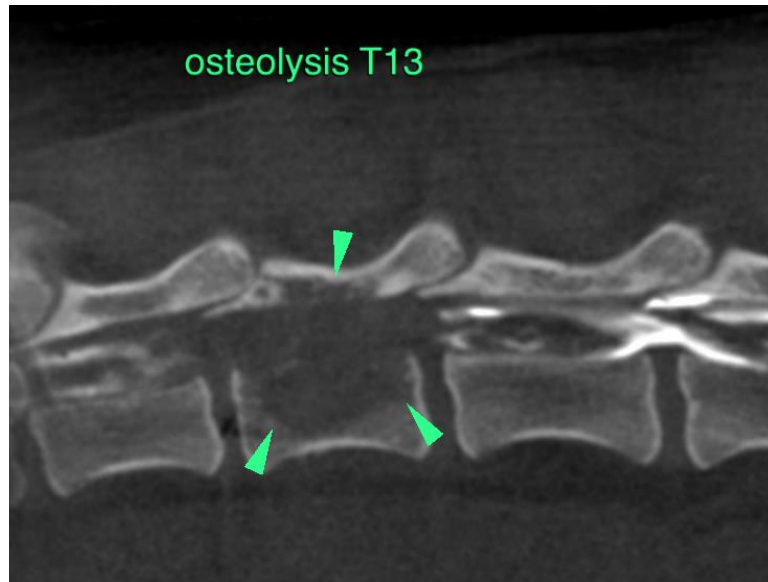
All Creatures
Veterinary Services

INVOICE

59904

DATE

8-24-23





PATIENT

Flipflop Barnaby

SPECIES

Canine

BREED

Mix Breed

SEX

Female

AGE

10 Years

INTERPRETED BY

Sebastian Schaub, DVM
Dr. med. vet. DipECVDI

HOSPITAL NAME

Animal Surgical
Center - Oceanside

REFERRING VET

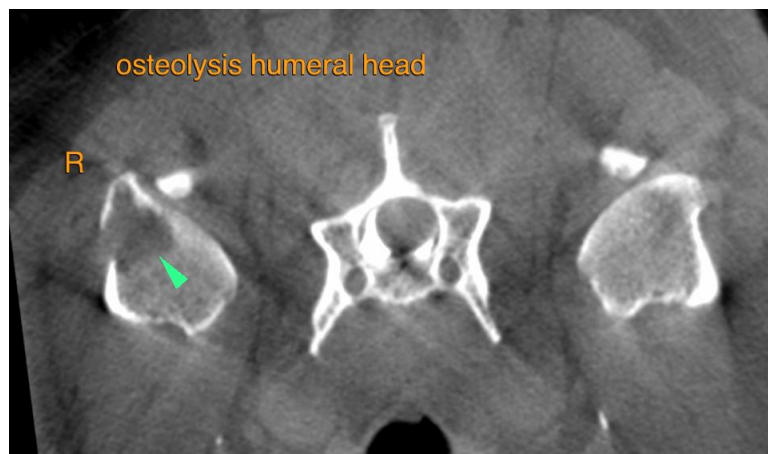
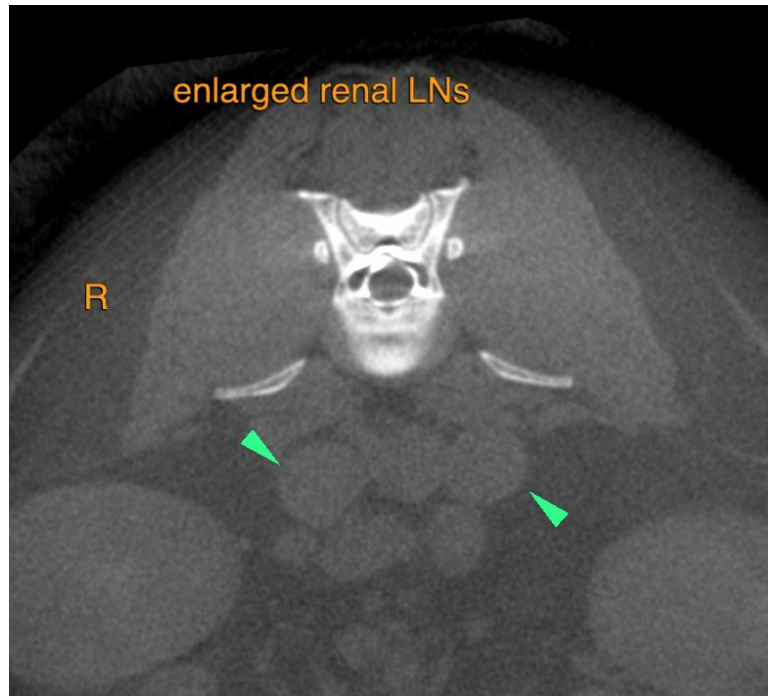
All Creatures
Veterinary Services

INVOICE

59904

DATE

8-24-23





PATIENT

Flipflop Barnaby

SPECIES

Canine

BREED

Mix Breed

SEX

Female

AGE

10 Years

INTERPRETED BY

Sebastian Schaub, DVM
Dr. med. vet. DipECVDI

HOSPITAL NAME

Animal Surgical
Center - Oceanside

REFERRING VET

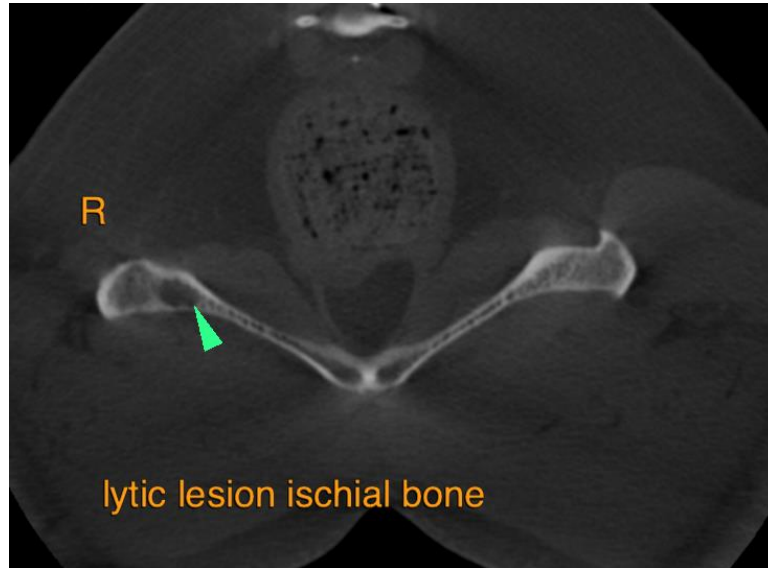
All Creatures
Veterinary Services

INVOICE

59904

DATE

8-24-23



The information and recommendations provided are based on the images presented by the referring veterinarian/sonographer. No evaluation can be communicated regarding pathology that was not visible in the image/video clips provided.

Thank you for this referral. If the clinical or image interpretation does not parallel your findings or if I can be of any further assistance please contact me.

Sebastian Schaub, Sebastian Schaub, DVM, Dr. med. vet. DipECVDI
info@sonopath.com