



PATIENT PRESENTING CLINICAL SIGNS

Parker Gutierrez Presented for ataxia. Left hind limb conscious paraparesis, proprioceptive deficits, and negative withdrawal reflex consistent with IVDD.

SPECIES COMPUTED TOMOGRAPHY OF THE THORACIC&LUMBAR SPINE

Canine A high resolution plain and myelographic CT study of the thoracic & lumbar spine is provided for review.

COMPUTED TOMOGRAPHIC FINDINGS

BREED Twelve thoracic vertebra and seven lumbar vertebra are present - THE LAST RIB BEARING VERTEBRA IS COUNTED AS T12.

Jack Russell The vertebral endplates T4/T5 and T5/T6 present mild spondylosis formation.

SEX

Post intrathecal contrast administration, the intervertebral discs C6/C7, L1/L2 is mildly bulging into the vertebral canal, distorting the ventral epidural space at the same level.

Spayed Female

The intervertebral discs T11/T12, T12/L1, L2/L3, L3/L4 and L4/L5 are moderately bulging into the vertebral canal, compressing the ventral subarachnoid space and mildly distorting the spinal cord at the same level.

AGE

The vertebral endplates L7/S1 present moderate spondylosis formation.

11 Years

COMPUTED TOMOGRAPHIC DIAGNOSIS

- Intervertebral disc protrusion T11/T12, T12/L1, L2/L3, L3/L4 and L4/L5 with compressive myelopathy
- Intervertebral disc protrusion C6/C7, L1/L2 with possible dynamic spinal cord compression
- Spondylosis deformans
- Cholecystolithiasis without evidence of obstruction

INTERPRETED BY

Sebastian Schaub, DVM
Dr. med. vet. DipECVDI

HOSPITAL NAME

Mobile Pet Imaging

INTERPRETATION OF THE FINDINGS & FURTHER RECOMMENDATIONS

Multiple intervertebral discs are protruding into the vertebral canal, the protrusions are considered chronic, but acute on chronic discopathy might have caused exacerbation of clinical signs. At this point I would recommend conservative management by the means of pain management and physical therapy.

REFERRING VET

Meaux

INVOICE

53704

DATE

8-24-22



PATIENT

Parker Gutierrez

SPECIES

Canine

BREED

Jack Russell

SEX

Spayed Female

AGE

11 Years

INTERPRETED BY

Sebastian Schaub, DVM
Dr. med. vet. DipECVDI

HOSPITAL NAME

Mobile Pet Imaging

REFERRING VET

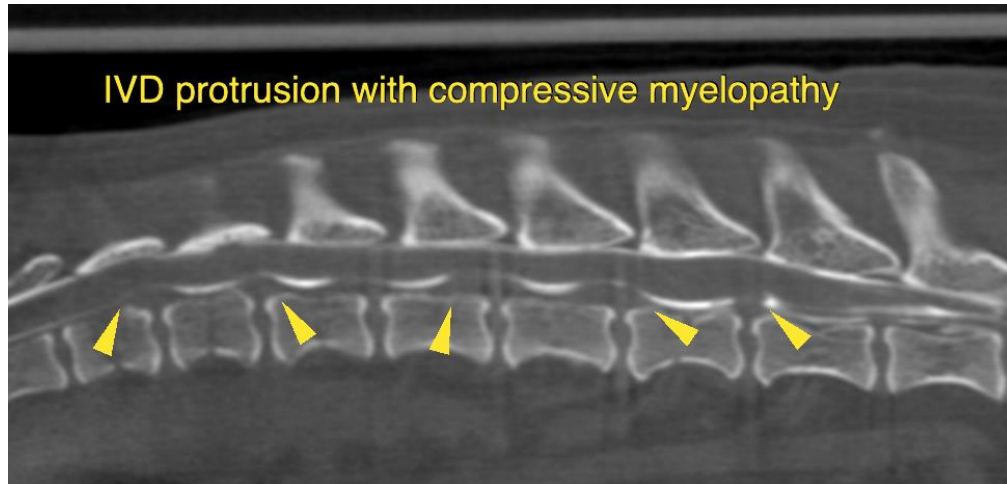
Meaux

INVOICE

53704

DATE

8-24-22



The information and recommendations provided are based on the images presented by the referring veterinarian/sonographer. No evaluation can be communicated regarding pathology that was not visible in the image/video clips provided.

Thank you for this referral. If the clinical or image interpretation does not parallel your findings or if I can be of any further assistance please contact me.

Sebastian Schaub, Sebastian Schaub, DVM, Dr. med. vet. DipECVDI
sebast.schaub@gmail.com