



PATIENT PRESENTING CLINICAL SIGNS

Nash Wing Met check

RADIOGRAPHIC STUDY OF THE THORAX

SPECIES Radiographs of the thorax in three imaging planes are provided for review.

K9 **RADIOGRAPHIC FINDINGS**

The surrounding bony structures are within normal limits.

BREED The extrathoracic soft tissues present homogeneous without abnormalities.

Lab Mix The heart is of normal size and shape, there is no evidence of cardiac chamber or vascular enlargement. The pulmonary vasculature is within normal limits.

SEX The cranial mediastinum presents the expected soft tissue opacity. The mediastinal width is less than twice the width of the vertebral column at the same level.

NM The trachea is normal in diameter and presents the anticipated course. The luminal outline of the trachea is smooth.

AGE The bronchial tree presents with thin walls and tapers uniformly towards the periphery as expected.

11 The lung parenchyma presents the expected architecture and opacity; the intrapulmonary vascular branching is seen up to the third order lung vessels.

INTERPRETED BY

Sebastian Schaub, DVM
Dr. med. vet. DipECVDI

The diaphragm is well delineated with even surface and the expected mild cranial bulging of the diaphragmatic cupola.

RADIOGRAPHIC DIAGNOSIS

HOSPITAL NAME

- Normal thorax

INTERPRETATION OF THE FINDINGS & FURTHER RECOMMENDATIONS

The radiographic study of het thorax is negative for pulmonary metastatic disease. The multiple small punctuate opacities throughout the lung field are considered as end-on vessels ± pulmonary osteomas.

All Creatures Animal
Hospital Stuart

REFERRING VET

Dr Mary Bressman

INVOICE

53982

DATE

8-24-22



PATIENT

Nash Wing

SPECIES

K9

BREED

Lab Mix

SEX

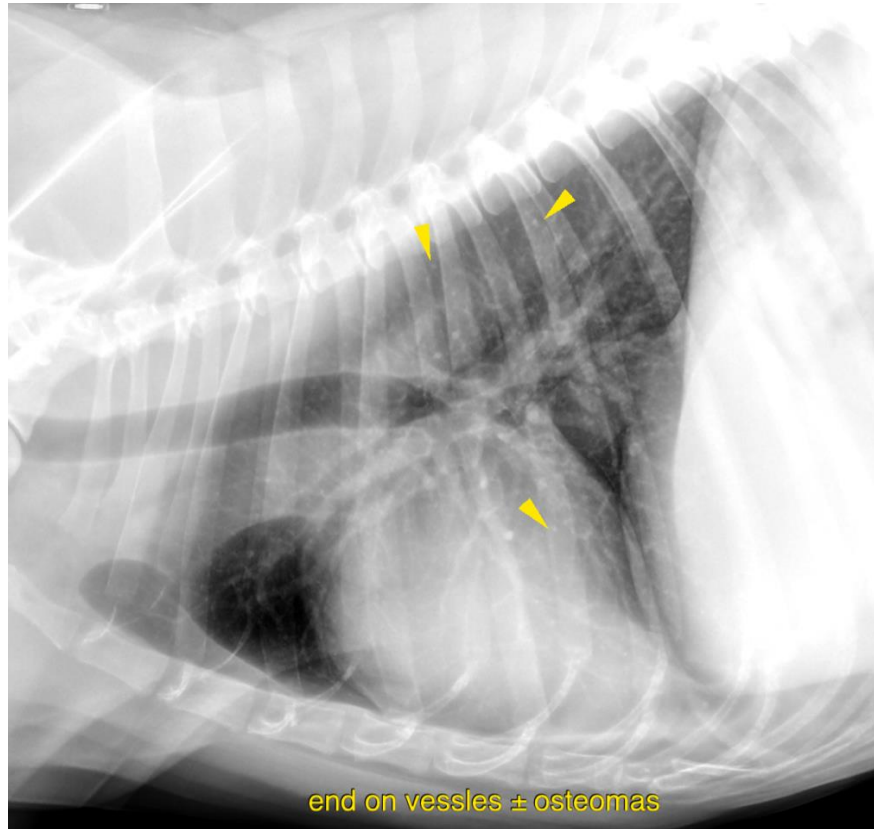
NM

AGE

11

INTERPRETED BY

Sebastian Schaub, DVM
Dr. med. vet. DipECVDI



HOSPITAL NAME

All Creatures Animal
Hospital Stuart

REFERRING VET

Dr Mary Bressman

INVOICE

53982

DATE

8-24-22

The information and recommendations provided are based on the images presented by the referring veterinarian/sonographer. No evaluation can be communicated regarding pathology that was not visible in the image/video clips provided.

Thank you for this referral. If the clinical or image interpretation does not parallel your findings or if I can be of any further assistance please contact me.

Sebastian Schaub, Sebastian Schaub, DVM, Dr. med. vet. DipECVDI
sebast.schaub@gmail.com