



PATIENT PRESENTING CLINICAL SIGNS

Nova Meyrick History: Chronically elevated liver enzymes, elevated bile acids. Rule out liver shunt.
Abnormal PE/Chem/CBC/UA Results: ALT 602, GGT 42, Bile acids 20.9, post 115.1

SPECIES COMPUTED TOMOGRAPHIC STUDY OF THE ABDOMEN

Canine A high resolution pre- and post-contrast CT study of the abdomen are provided for review.

COMPUTED TOMOGRAPHIC FINDINGS

BREED

Chihuahua The serosal fat presents normal attenuation behavior. There is no evidence of peritoneal effusion or peritonitis.

SEX

Both kidneys present within normal limits for size, shape and organ architecture. After contrast administration a bilaterally symmetric and uniform nephro- and pyelogram is noted.

Spayed Female

The adrenal glands are within normal limits for size, shape and organ architecture.

AGE

Both liver and spleen present with normal shape, even surface, uniformly attenuating parenchyma and homogeneous contrast enhancement, unremarkable.

4 Years

The portal vein presents a normal order of its tributary veins and intrahepatic branching. No abnormal vessel is noted inside and outside of the liver parenchyma.

INTERPRETED BY

Sebastian Schaub,
DVM Dr. med. vet.
DipECVDI

The pancreas is evenly contoured, the pancreatic parenchyma is homogeneous and presents uniform contrast enhancement.

The position, delineation, wall and content of the gastrointestinal tract are considered within normal limits throughout.

HOSPITAL NAME

Mobile Pet Imaging

The bony and surrounding soft tissue structures reveal no abnormalities.

COMPUTED TOMOGRAPHIC DIAGNOSIS

REFERRING VET

Meaux

- No evidence of portosystemic shunting, neither intra- nor extrahepatic

INTERPRETATION OF THE FINDINGS & FURTHER RECOMMENDATIONS

INVOICE

12729

No macroscopic vascular bypass of the liver was noted in the pre- and post contrast studies of the abdomen. However if the clinical signs are consistent with insufficiency of the liver, primary non-cirrhotic portal hypertension (microvascular dysplasia) or other diffuse parenchymal liver disease would still be a potential and should be ruled out by means of ultrasound guided or surgical liver biopsy.

DATE

8/24/21



PATIENT

Nova Meyrick

In general ultrasound guided Tru-cut biopsies of the liver may be performed with reasonably low potential for complications under the following conditions: platelet count > 50*103/μl, <25% prolongation of PT/PTT – less of deviation from normal values acceptable in presence of peritoneal effusion. The intensity of the post procedural patient monitoring needs to be tailored to the degree of deviation from normal reference ranges.

SPECIES

Canine

BREED

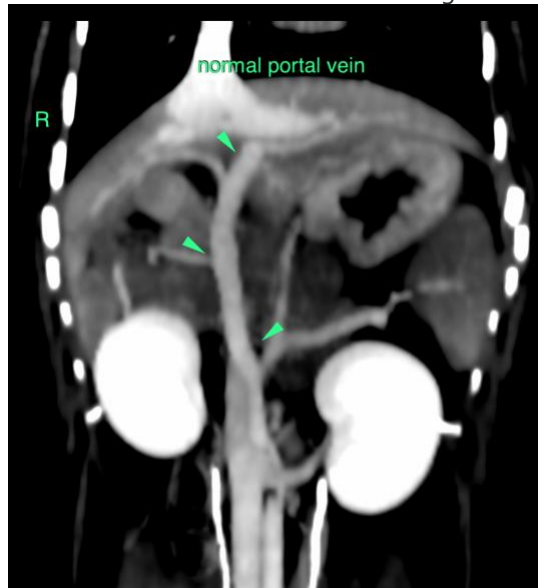
Chihuahua

SEX

Spayed Female

AGE

4 Years



INTERPRETED BY

Sebastian Schaub,
DVM Dr. med. vet.
DipECVDI

The information and recommendations provided are based on the images presented by the referring veterinarian. No evaluation can be communicated regarding pathology that was not visible in the image/video clips provided.

Thank you for this referral. If the clinical or image interpretation does not parallel your findings or if I can be of any further assistance please contact me.

HOSPITAL NAME

Mobile Pet Imaging

Sebastian Schaub, Sebastian Schaub, DVM, Dr. med. vet. DipECVDI
sebast.schaub@gmail.com

REFERRING VET

Meaux

INVOICE

12729

DATE

8/24/21